

Carcinosarcoma of The Rectum Presenting as an Intraabdominal Abscess

Ümit Sekmen¹, Hüseyin Bircan²

¹Acıbadem Fulya Hospital, Clinic of General Surgery, İstanbul, Turkey

²Başkent University Hospital, Department of General Surgery, İstanbul, Turkey

ABSTRACT

Carcinosarcoma is a very rare type of a tumor and tends to occur in the proximal part of the digestive tract. We present an extremely rare case of a carcinosarcoma of the rectum with closed perforation and abscess formation. An 86 year-old woman was operated on with the diagnosis of intraabdominal abscess and a low anterior resection and a Hartmann procedure was performed. Histopathological diagnosis of the tumor was carcinosarcoma. No adjuvant therapy was suggested by our oncology department because of the advanced age and comorbid cardiac and respiratory illnesses of the patient.

Key words: rectum, carcinosarcoma, intraabdominal abscess

İNTRAABDOMİNAL APSE İLE KENDİNİ GÖSTEREN REKTUM KARSİNOSARKOMU

ÖZET

Karsinosarkoma oldukça nadir görülen agresif seyirli bir tümördür. Genellikle sindirim sisteminin proksimal kısmında görülürler. Bu vaka takdiminde kapalı perforasyon ve intraabdominal apse oluşturmuş rektum proksimaline yerleşik tümörü olan 85 yaşında bir bayan hastayı sunmaktayız. Low anterior rezeksiyon-Hartman prosedürü uygulanan hastanın histopatolojik incelemesi sonucu carcinosarcoma olduğu görülmüştür. Onkoloji bölümü hastaya yaş, kardiyak ve solunum sorunları sebebiyle adjuvan tedavi vermeyi uygun bulmamıştır.

Anahtar kelimeler: rektum, carcinosarkom, intraabdominal apse

Carcinosarcoma is a very rare type of a tumor and tends to occur in the proximal part of the digestive tract. We present an extremely rare case of a carcinosarcoma of the rectum with closed perforation and abscess formation.

Case Report

An 86 year-old woman was contraversial admitted to our hospital with diarrhea, abdominal pain, nausea, vomiting, and weight loss of 8 kg in the last 6 months. On physical examination, she had moderate abdominal distention, guarding, and rebound tenderness in both lower quadrants. Her WBC was 18.000/mm³, hsCRP was 113 mg/L and Hb was 10,4 g/dl. Abdominal computed tomography revealed a pelvic necrotic mass measuring 9x6 cm (Figure 1).

She was operated on with the diagnosis of intraabdominal abscess. Exploratory laparotomy revealed a mass lesion of 10 x 15 cm at the rectosigmoid junction. A tumor could be felt in it originating from the colorectum. It was not possible to dissect the mass altogether; therefore, the abscess was drained first. Draining the abscess disclosed that there was a perforated tumor in the colonic wall. To include another mass lesion palpated 5-6 cm distal to the tumor with a 5 cm of distal margin, a low anterior resection and a Hartmann procedure was performed. Early postoperative period was complicated with acute renal failure and pulmonary problems. IV antibiotic treatment was continued to 21 days and the patient was discharged in good health. No adjuvant therapy was suggested by our oncology department because of the advanced age and comorbid cardiac and respiratory illnesses of the patient. She is currently in the fifth postoperative month.

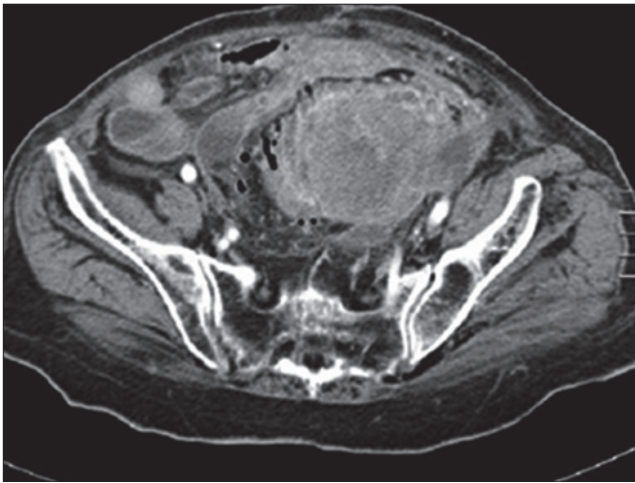


Figure 1. Abdominal computed tomography of a patient with carcinosarcoma of the rectum.

Abdominal CT with IV contrast demonstrated an intrapelvic necrotic mass (9 x 6 cm). No oral contrast was administered since the patient had acute abdomen and was planned to be operated on early.

Histological examination revealed a 4.5 x 4 x 4 cm tumor with necrosis and hemorrhage and serosal perforation, infiltrating the full thickness of the bowel wall; however, the mucosa was intact. Histopathological diagnosis of the tumor was carcinosarcoma (Figure 2). The tumor consisted of overlapping areas of poorly differentiated adenocarcinoma and indifferently differentiated sarcoma with chondroid differentiation in focal areas. In addition, there was a 2.5 cm polyp displaying features of a well differentiated adenocarcinoma originating from a tubulovillous adenoma 5 cm distal to the primary tumor. Three of the seven lymph nodes extracted were metastatic. The sarcomatous component was immunoreactive for vimentin and it was negative for pancytokeratine.

Discussion

About twenty cases of colonic carcinosarcomas have been reported after the first report of Weidner in 1986 (1). These tumors are seen slightly more frequently among women. Skin, lung, breast, eye, head and neck are the sites where carcinosarcomas tends to occur mostly (2,3,4). In the gastrointestinal tract, carcinosarcoma arises predominantly in the oesophagus, stomach and biliary tract (5,6); whereas carcinosarcoma of the large intestine has been reported only rarely.

The histogenesis of carcinosarcoma is uncertain. The collision theory and the monoclonal origin theory are popular theories; however, recent molecular studies support the latter. According to this theory, a common stem cell origin for both cell components or metaplastic transformation of one neoplastic cell into the other may be the mechanism of carcinosarcoma formation. This could be either due to

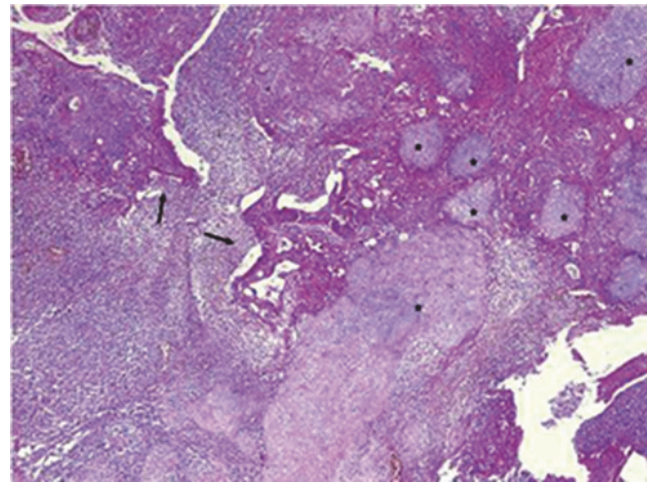


Figure 2. Rectal carcinosarcoma. Arrows show poorly differentiated carcinomatous cells where stars represent area of chondrosarcoma (H&E, 200X)

a malignant transformation of a pluripotential stem cell capable of both epithelial and mesenchymal differentiation (the combination theory) or due to a sarcomatoid carcinomatous differentiation of a carcinoma or sarcoma (the conversion theory) (1,7,8). For carcinosarcomas developing in the digestive system organs, the metaplastic theory is supported, which also explains that in most cases, the carcinoma component precedes and that it is differentiated into the sarcomatoid component in accordance with the development of cancer clones (12).

Although a few cases with two to four years of survival were reported, prognosis is generally poor even after surgical resection (6). About 30% of the cases reported were metastatic when diagnosed, and another 40% metastasized during follow-up (5). The effectiveness of adjuvant therapy for these patients is controversial; however, since the metastatic component tends to metastasize predominantly, oncologists usually suggest chemotherapy following colon adenocarcinoma guidelines in these patients (5,6,9). Chemotherapy with 5-FU FL therapy (UFT+leucovorin) can be administered with capecitabine or MMC instead of treatment together with cisplatin have also been administered to patients with metastasis in lymph nodes in accordance with colon cancer therapy, but still a satisfactory treatment effect has not been obtained as yet (3,5,7,9,10,11).

This case demonstrated that carcinosarcoma may cause perforation and intra abdominal abscess formation, and diarrhea probably due to partial intestinal obstruction. It may mimic acute gastroenteritis especially in elderly patients. To our best knowledge, this is the first case of a carcinosarcoma of the colon with closed perforation and abscess formation.

References

1. Jeong YJ, Lee MR, Kim JC, Hwang PH, Moon WS, Chung MJ. Carcinosarcoma of the rectosigmoid colon in a 13-year-old girl. *Pathol Int.* 2008 Jul;58(7):445-50.
2. Wick MR, Swanson PE. Carcinosarcomas: current perspectives and an historical review of nosological concepts. *Semin Diagn Pathol* 1993; 10: 118-27.
3. Weidner N, Zekan P. Carcinosarcoma of the colon. Report of a unique case with light and immunohistochemical studies. *Cancer* 1986; 58: 1126-30.
4. Ishida H, Ohsawa T, Nakada H, et al. Carcinosarcoma of the rectosigmoid colon: report of a case. *Surg Today* 2003; 33: 545-9.
5. Ambrosini-Spaltro A, Vaira V, Braidotti P, Rovati MP, Ferrero S, Bosari S. Carcinosarcoma of the colon: report of a case with morphological, ultrastructural and molecular analysis. *BMC Cancer.* 2006 Jul 12;6:185.
6. Tsekouras DK, Katsaragakis S, Theodorou D, Kafiri G, Archontovasilis F, Giannopoulos P, Drimousis P, Bramis J. Rectal carcinosarcoma: A case report and review of literature. *World J Gastroenterol* 2006 March 7;12(9):1481-1484
7. Kim JH, Moon WS, Kang MJ, Park MJ, Lee DG. Sarcomatoid carcinoma of the colon: a case report. *J Korean Med Sci* 2001; 16: 657-660
8. Aramendi T, Fernandez-Acenero MJ, Villanueva MC. Carcinosarcoma of the colon: report of a rare tumor. *Pathol Res Pract* 2003; 199: 345-348
9. Bertram P, Treutner KH, Lietze L, Schumpelick V: True carcinosarcoma of the colon. *Langenbecks Arch Chir* 1997, 382:173-174.
10. Shoji M, Dobashi Y, Iwabuchi K. Sarcomatoid carcinoma of the descending colon – a histological, immunohistochemical and ultrastructural analysis. *Acta Oncol.* 1998;37:765–768.
11. Di Vizio D, Insabato L, Conzo G. Sarcomatoid carcinoma of the colon: a case report with literature review. *Tumori.* 2001;87:431–435.
12. Matsumoto T, Fujii H, Arakawa A. Loss of heterozygosity of analysis shows monoclonal evolution with frequent genetic progression and divergence in esophageal carcinosarcoma. *Hum Pathol.* 2004;35:322–327.