

# Ileocecal Intussusception Secondary to Ileal Lipoma in an Adult Patient

Bülent Yaşar<sup>1</sup>, Ömer Avlanmış<sup>2</sup>, Yasin Ağırnak<sup>3</sup>

<sup>1</sup>Çamlıca Erdem Hastanesi, Gastroenterohepatoloji, İstanbul, Türkiye

<sup>2</sup>Çamlıca Erdem Hastanesi, Genel Cerrahi, İstanbul, Türkiye

<sup>3</sup>Çamlıca Erdem Hastanesi, Radyoloji, İstanbul, Türkiye

## ABSTRACT

Intussusception is a relatively common cause of intestinal obstruction in children but a rare clinical entity in adults. Ileal lipomas are uncommon nonepithelial neoplasms that are generally found incidentally during endoscopies, surgery, or autopsy. In this manuscript, we present a case of ileal lipoma that became symptomatic with abdominal pain episodes and ileocecal intussusception, treated with surgical resection.

**Key words:** intussusception, ileal lipoma

## ERİŞKİN BİR HASTADA İLEAL LİPOMA BAĞLI İLEOÇEKAL İNTUSSUSEPSİYON

### ÖZET

İntussusepsiyon, çocuklarda bağırsak tıkanıklığının sık görülen bir nedenidir ancak erişkinde nadir görülen bir klinik tablodur. İleal lipomlar, genellikle endoskopi, cerrahi veya otopsi sırasında tesadüfen saptanan, nadir nonepitelyal tümörlerdir. Bu yazıda, karın ağrısı episodları ve ileoçekal intussusepsiyon ile semptomatik hale gelen ve cerrahi rezeksiyon ile tedavi edilen bir ileal lipom vakası sunmaktayız.

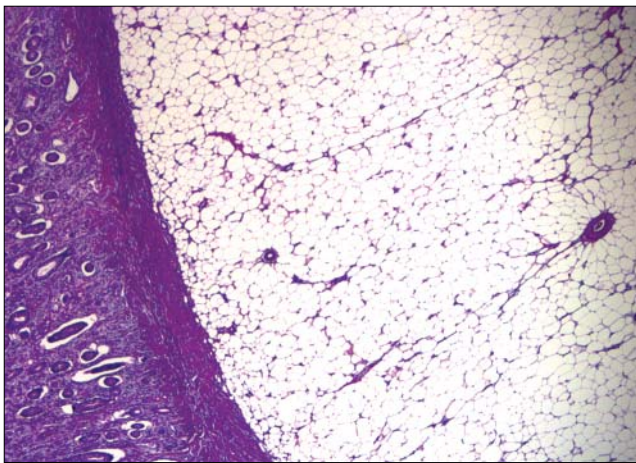
**Anahtar sözcükler:** intussusepsiyon, ileal lipom

**A** 58-year old female was admitted to the Emergency Department with diffuse abdominal pain, distention and vomiting. She had a 3-year history of intermittent and crampy abdominal pain which was greatest in the right lower quadrant. She appeared moderately ill. Abdominal examination revealed diffuse tenderness on palpation, especially in the right lower quadrant and bowel sounds were increased in auscultation. Laboratory results were unremarkable. After resuscitation, the target lesion in the right lower quadrant with obstruction of contrast and dilatation of the small intestine was detected by computed tomography (CT). The lesion was 4 cm in diameter and showed a density of lipoma (Figure 1). Laparotomy was performed and invagination of the distal ileum through the ileocecal valve into the cecum was observed with ischemic changes. Segmental resection and ileo-colonic anastomosis were carried out.

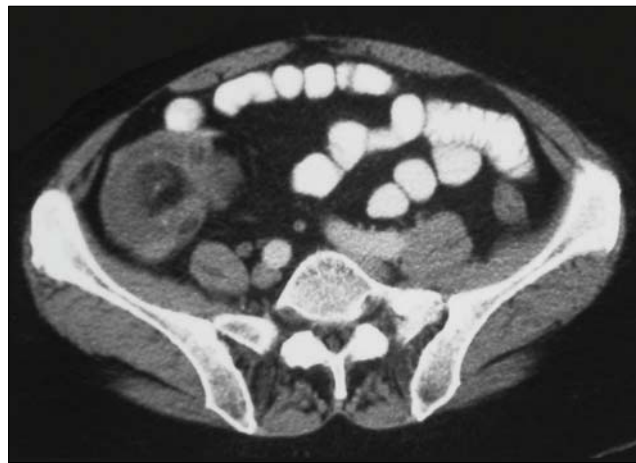Histopathological diagnosis was reported as small bowel lipoma located submucosally (Figure 2). The patient was discharged from hospital in good condition on the 5th day after resection.

## Discussion

Intussusception is defined as the telescoping of a proximal part of the bowel along with its mesentery into an adjacent segment (1). It is a common entity in the paediatric population especially in the first two years of life (90-95% of cases), but it is an uncommon condition in adults, accounting for only 5% of all cases, and 1-5% of small bowel obstruction (2). While 90% of adult intussusceptions have an organic cause, 60% of cases develop due to neoplasms (60% malignant and 24-40% benign). Adult colonic intussusception is caused by a primary carcinoma in 65-70% of all cases (3). Although inflammatory lesions, Meckel's diverticulum, polyps, and extraluminal lesions such as adhesions, lymphomas and



**Figure 1.** Histopathological findings showed an intestinal lipoma (H&Ex40).



**Figure 2.** Abdominopelvic CT scan showed intramural, fat density mass in the ileum.

metastases have also been widely reported. Colonic lipoma as a leading cause is uncommon but is more often observed in females with a peak incidence between 50 and 60 years old (4). Most are found in the cecum, located submucosally (5). Several possible mechanisms have been suggested to explain this situation: (a) a tumor may act as a foreign body causing violent peristalsis, so that the contracted central part of the bowel easily moves into the dilated distal part; (b) intussusception may be due to the altered muscle function caused by a tumor or bowel paralysis; and (c) a tumor may be grasped and pulled forward by traction (6).

The classic triad of intermittent abdominal pain, bloody diarrhea, and a palpable tender mass has been described in children (7). However, abdominal distension, bleeding, nausea and vomiting are the common but non-specific symptoms of intussusception in adults. However, only about 9% to 10% of adult intussusceptions present with the typical triad. Due to the non-specific and intermittent nature of the symptoms, and difficulty with the examination of the small intestine, preoperative diagnosis is generally challenging (8). In most cases intussusception is ileocolic, where the small intestine penetrates into the colon through the ileocaecal valve; in other cases it could be ileoileal and colocolic. Imaging methods, especially CT, are required to make the diagnosis. CT has a sensitivity of 58–100% and a specificity of 57–71% in determining the etiology. A “target sign” or a “sausage shaped” mass with different layers of attenuation can be shown in CT. Ultrasonography, especially useful in children, is easy to perform and non-invasive. Classic features such as “target”, “donut” signs or pseudokidney can be revealed

on US, but image interpretation can be difficult in the presence of air. (9).

Lipomas are rare benign tumors, representing 2.6% of non-malignant tumors of the intestinal tract (10). They usually arise from adipocytes in the submucosa (90%) and occasionally in the subserosa and mainly occur singly in elderly patients. Lipomas are found most commonly in the colon (65–75%), especially in the right side followed by transverse colon, descending colon, sigmoid and rectum. 20–25% occur in the small intestine, most frequently in the ileum (11).

Most lipomas are asymptomatic and found incidentally, but those exceeding 2 cm diameter may produce symptoms such as intussusception, obstruction or hemorrhage. Lipomas can be diagnosed with endoscopy, capsule endoscopy, barium enemas, CT and US. It lends an intense yellow color to the mucosa because of the underlying accumulated fat during endoscopy. On CT, lipomas are seen as well-circumscribed, ovoid or round with sharp margins, and homogenous mass. In addition, they demonstrate characteristic attenuation values between –40 and –120 HU typical of the fatty composition. The most important point in the diagnosis of intestinal lipomas is that they must be distinguished from a malignant colonic neoplasm, so the gold standard of diagnosis is the histopathology examination (12).

The treatment for small bowel lipomas depends on the clinical manifestations and size. It is not clear whether asymptomatic small lipomas require any intervention, but conservative treatment is often indicated (13). Surgery is the recommended treatment if the lipoma is symptomatic or to rule out liposarcomas by performing a histological

examination. Error in diagnosis can lead to inappropriate surgery such as an unnecessary radical resection because of an erroneous preoperative diagnosis of colon cancer. The correct diagnosis of gastrointestinal lipomas is usually made intraoperatively and confirmed by final surgical pathology. When possible, an intraoperative biopsy

with frozen section may provide an accurate diagnosis to guide surgery.

In conclusion, lipomas must be kept in mind as a rare cause of intussusception in adults and the treatment is surgical resection of the intestinal segments involved.

## References

1. Ibrahim D, Patel NP, Gupta M, Fox JC, Lotfipour S. Ileocecal intussusception in the adult population: case series of two patients. *West J Emerg Med* 2010;11:197-200.
2. Muroi M, Liverani A, Urbano D, Catracchia V, Marino G. Adult ileocaecal and colic invagination: a case report. *Chir Ital* 2008;60:749-53.
3. Krasniqi AS, Hamza AR, Salihu LM, Spahija GS, Bicaj BX, Krasniqi SA, et al. Compound double ileoileal and ileocecolic intussusception caused by lipoma of the ileum in an adult patient: A case report. *J Med Case Rep* 2011;5:452.
4. Wang N, Cui XY, Liu Y, Long J, Xu YH, Guo RX, et al. Adult intussusception: a retrospective review of 41 cases. *World J Gastroenterol* 2009;15:3303-8
5. Ghidirim G, Mishin I, Gutsu E, Gagauz I, Danch A, Russu S. Giant submucosal lipoma of the cecum: report of a case and review of literature. *Rom J Gastroenterol* 2005;14:393-6.
6. Rogers SO, Lee MC, Ashley SW. Giant colonic lipoma as lead point for intermittent colo-colonic intussusception. *Surgery* 2002;131:687-8.
7. Harrington L, Connolly B, Hu X, Wesson DE, Babyn P, Schuh S. Ultrasonographic and clinical predictors of intussusception. *J Pediatr* 1998;132:836-9.
8. Azar T, Berger DL. Adult intussusception. *Ann Surg* 1997;226:134-8.
9. Chugthai SZ, Atif AH, Chughtai JZ, Miptah NH, Couse N. Adult ileocolic intussusception secondary to ileocaecal valve polyp. *BMJ Case Reports* 2010;2010.
10. Mayo CW, Pagtalunan RJ, Brown DJ. Lipoma of the alimentary tract. *Surgery* 1963;53:598-603.
11. Balamoun H, Doughan S. Ileal lipoma – a rare cause of ileocolic intussusception in adults: Case report and literature review. *World J Gastrointest Surg* 2011;3:13-5.
12. Dultz LA, Ullery BW, Sun HH, Huston TL, Eachempati SR, Barie PS, et al. Ileocecal valve lipoma with refractory hemorrhage. *JLS* 2009;13:80-3.
13. Alberti D, Grazioli L, Orizio P, Matricardi L, Dughi S, Gheza L, et al. Asymptomatic giant gastric lipoma: what to do? *Am J Gastroenterol* 1999;94:3634-37.