

A Rare Cause of Unilateral Hydronephrosis

Tufan Çiçek¹, Umur Gönülalan¹, Gökçen Çoban², Hilal Erinaç³, Bülent Öztürk¹

¹Başkent University Application and Research Center, Urology Department, Konya, Turkey

²Başkent University Application and Research Center, Radiology Department, Konya, Türkiye

³Başkent University Application and Research Center, Radiology Department, Patoloji, Konya, Türkiye

ABSTRACT

Endometriosis is characterized with existing of endometrial cells outside of uterus. Endometriosis usually effects ovaries, fallopian tubes and uterine ligaments. It rarely places on ureter. We presented a 42 year-old female patient with lumbar pain and dysuria referred to our clinic. Urinary sediment showed microscopic hematuria and imaging studies with left renal hydronephrosis. Projecting into the lumen of the ureter showed a mass in the diagnostic ureterorenoscopy. We performed distal ureterectomy and ureteroneocystostomy in the treatment of ureteral mass. Microscopic evaluation of the ureteral mass showed endometriosis. Endometriosis should be considered as a rare cause of hydronephrosis in female patients with an undetectable stone in imaging studies.

Key words: Endometriosis, hydronephrosis, ureteric endometriosis

TEK TARAFLI HİDRONEFRONEFROZUN NADİR NEDENİ: ÜRETERAL ENDOMETRİOZİS

ÖZET

Endometriosis, endometrium dokusunun uterus dışında yerleşmesidir. Çoğunlukla overler, fallop tüpleri ve uterin ligamentleri etkiler. Daha az sıklıkta üreterde de yerleşim gösterebilir. 42 yaşında, kadın hasta lomber ağrı ve dizüri yakınması ile başvurdu. İdrar sedimentinde mikroskopik hematüri ve görüntüleme çalışmalarında sol renal hidronefroz saptandı. Tanısal üreteroskopisinde lümene projekte kitle izlendi. Hastaya segmenter üreter rezeksiyonu ve üreteroneostomi uygulandı. Mikroskopik incelemede üreter yerleşimli endometriosis saptandı. Görüntüleme yöntemleriyle taş tespit edilemeyen bayan hastalarda hidronefrozun nadir nedeni olan endometriosis akılda tutulmalıdır.

Anahtar sözcükler: Endometriosis, hidronefroz, ureteral endometriosis

Introduction

Endometriosis is used to describe active and progressive endometrial tissue exterior to the uterine cavity (1). Endometrial tissue is sensitive to changes in estrogen and progesterone during the menstrual cycle. Endometriosis usually effects ovaries, fallopian tubes and uterine ligaments (2). Less frequently, can be placed in the liver, heart, pleura, gastrointestinal and urinary system (3-4), and can mimic primary and metastatic tumors of the affected organs. Rarely, ureteral endometriosis may lead to hydronephrosis as a result of adhesions and scar formation. Here we present a case of ureteral endometriosis in a woman with remitting left flank pain and hydronephrosis.

Case report

a 42-years-old woman was referred to our Urology department with the history of relapsing and remitting left flank pain, dysmenorrhea, dysuri and dyspareunia about 7 months. Her flank pain was increased especially with menstrual cycle in the last two months. Her sister had a history of endometriosis in the bladder. She did not receive a hormonal therapy before. She had two children and her menstrual cycles were normal. She did not any vaginal discharge. Routine blood tests and renal functional tests were normal. Urine analysis showed 20 red blood cells. Urine culture was normal. Pelvic ultrasonography revealed grossly hydroureteronephrosis with no evidence of calculi. A contrasted abdominal computed tomography (CT) was performed, and CT revealed left

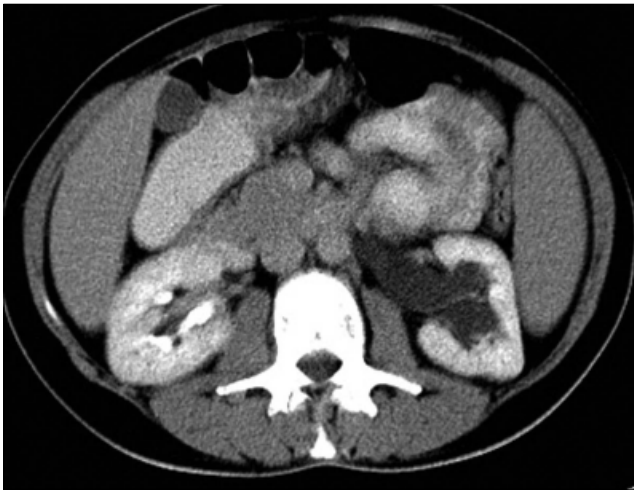


Figure 1. On axial CT imaging after contrast media administration, there is left side hydronephrosis due to distal ureteral obstruction.

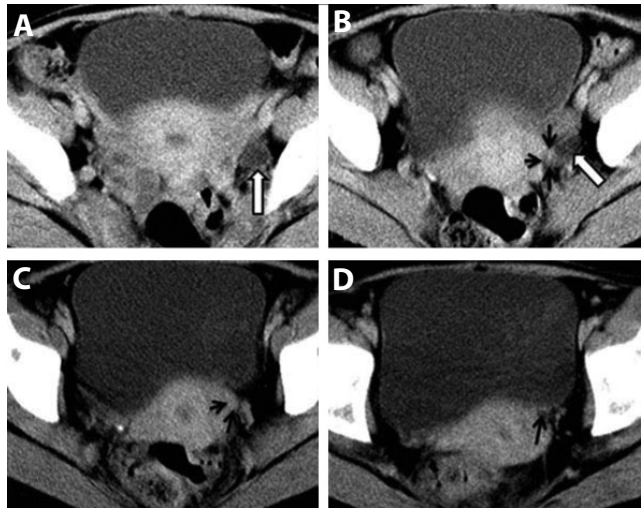


Figure 2 A-D. On axial serial (A-D) CT imaging after contrast media administration, ureteral dilatation (white arrows) and intraureteral enhanced soft tissue mass (black arrows) is clearly seen.

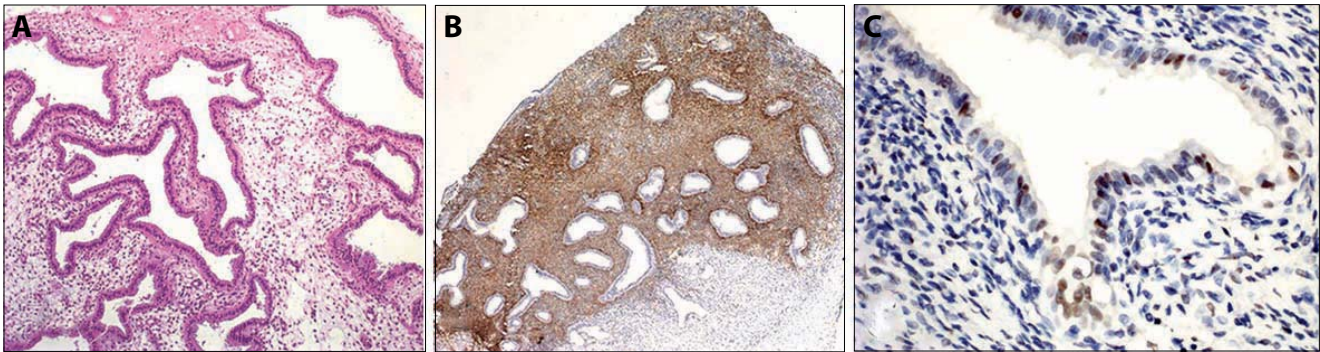


Figure 3 A-C. Microscopic sections showing the endometrial tissue which was composed of sparse endometriotic stroma and the endometriotic glands, many of which are cystic (A). Immunohistochemical examination revealed that the periglandular endometrial stroma was immunoreactive for CD10 and the glands was immunoreactive for ER (B and C).

side hydronephrosis (Figure 1), and severe obstruction of left distal ureter by an intraureteral enhanced soft tissue mass (Figure 2). On the cystoscopic examination of bladder and both of the ureter orifice were normal. Diagnostic ureterorenoscopy showed well defined, white pallor colored soft tissue mass projecting in the left intrinsic distal ureteral lumen. There was a fair dilatation at ureteral segment above the mass. We decided to perform distal ureterectomy due to the suspect mass in distal ureteral segment.

We performed distal ureterectomy and ureteroneocystostomy. In these operation, we have reached to distal ureter by using previous Pfannenstiel incision and tried to pick out distal ureter from dense fibrotic tissue but failed in this approach. We excised the distal ureteral segment. So that by using Politano-Leadbetter technique ureteroneocystostomy was performed and double-j stent was inserted.

The resected part of the distal ureter segment was examined by pathologist. We removed the Foley catheter on the fourth postoperative day. The double-J stent was kept in at least 4 weeks postoperatively. Pathological examination revealed as ureteral endometriosis (Figure 3A, B, and C). After 3 months cystography evaluated as normal and the patient is in regular follow-up both urology and gynecology clinics

Discussion

Endometriosis is often observed during the reproductive period. Most cases are seen between the ages of 25-30 (5). Urinary tract endometriosis is a rare condition and could be found approximately %1 of women with pelvic endometriosis. It usually involves the bladder (5). Ureteral involvement is extremely rare and found to be %0,1 (6). There is a genetic predisposition in patients with family history. Location and extent of the disease determines

the severity of the symptoms. However, patients' symptoms may not be related to the degree of disease, and the disease can progress even nonspecific findings; include chronic pelvic pain, dysmenorrhea, and dyspareunia. Typical findings are renal colic, back pain and hematuria. However, 50% of patients may be asymptomatic (7). Often involvement is seen in the lower end of the ureter, and divided into two types based on infiltration instead. Extrinsic type involves ureteral adventitia, and intrinsic type involves muscularis mucosa (4). Endometriosis is a process that creates chronic inflammation and results in scarring and adhesion. Progressive stenosis of the ureter causes hydronephrosis and loss of kidney at random in some cases (8). Ultrasound, CT, magnetic resonance imaging and radiographic imaging techniques, such as intravenous-urography are common diagnostic tools. However, preoperative diagnosis is still difficult (8). Final diagnosis usually requires demonstration of endometrial tissue directly or confirmation by pathological examination. In other words, surgery is necessary for definitive diagnosis. Diagnostic laparoscopy is the frequently used method to observe the endometriosis foci better (9). However, this method may not provide sufficient contribution of diagnosis in patients with intrinsic ureteral endometriosis. Treatment of ureteral endometriosis is variable. Treatment

options for ureteral endometriosis are medical treatment (danazol, progestin), ureterolysis, psoas hitch, Boari flap, transureteroureterostomy and ileal interposition. All of them may be used if necessary (10). The choice of treatment depends on the age, symptoms, spread of disease and should be preferred by individuals. However, hormonal monotherapy is not recommended. The treatment of ureteral endometriosis is still unclear and usually requires a multidisciplinary approach. But the only certain thing is to make the correct preoperative determination of the level of ureteral stricture. Ureteroneocystostomy is the most appropriate approach to moderate and severe hydronephrosis.

Endometriosis is a very common gynecologic disorder in reproductive age women, but the localization in the urinary system can easily be skipped. Endometriosis should be considered as a rare cause of non-calculous hydronephrosis in women presenting with flank pain.

Conclusion

Treatment options should be preferred by individuals. However, open ureteroneocystostomy still remains one of the most important treatment options, in the cases accompanied by hydronephrosis due to ureteral stenosis.

References

1. Schindler AE. Dienogest of endometriosis in long term treatment. *Int J Womens Health* 2011; 3:175-84.
2. Westney O, Amundsen CI, McGuire EJ. Bladder endometriosis: Conservative management. *J Urol* 2000; 163:1814-7.
3. Waller KG, Lindsay P, Curtis P, Shaw RW. The prevalence of endometriosis in women with infertile partners. *Eur J Obstet Gynecol Reprod Biol* 1993; 48:135-9.
4. Yohannes P. Ureteral Endometriosis. *J Urol* 2003; 170:20-5.
5. Stillwell TJ, Kramer SA, Lee RA. Endometriosis of ureter. *Urology* 1986; 28:81-5.
6. Gabriel B, Nassif J, Trompoukis P, Barata S, Wattiez A. Prevalence and management of urinary Tract Endometriosis: A Clinical Cases Series. *Urology* 2011; 78:1269-74.
7. Comiter CV. Endometriosis of urinary tract. *Urol Clin North Am* 2002; 29: 625-635.
8. Ponticelli C, Graziani G, Montanari E. Ureteral Endometriosis: A Rare and Underdiagnosed Cause of Kidney Dysfunction. *Nephron Clin Pract* 2010; 114, c89-93. doi:10. 1159/000254380
9. Muse K. Clinical manifestations and classification of endometriosis. *Clin Obstet Gynecol* 198; 31:813-22.
10. Nishihara K, Kawai N, Hibino M et al. Clinical evaluation of ureteral endometriosis: report of 8 cases. *Hinyokika Kyo* 2003; 49:285-9.