

Testicular Epidermoid Cyst: A Case Report and the Review of the Literature

Burak Özkan¹, Enis Rauf Coşkun¹, Yeşim Sağlıcan², Veli Yalçın³

¹Acıbadem University School of Medicine, Department of Urology, İstanbul, Turkey

²Acıbadem University School of Medicine, Department of Pathology, İstanbul, Turkey

³Acıbadem Bakırköy Hospital, Department of Urology, İstanbul, Turkey

ABSTRACT

Epidermoid cysts account for% 1 to% 2 of all orchiectomy masses and tend to occur as palpable solitary masses like testis tumors. These are benign lesions without malignant potential and conservative management such as testis sparing surgery is generally preferred over orchiectomy if possible. No cases of local recurrence or metastases have been reported. Here in we report a 26 years old man which came to our clinic with a painless right testicular mass. Color doppler ultrasonography demonstrated a large right testis with 2 round parenchymal lesions. Serum testicular germ cell tumor markers were normal. Abdominal computed tomography demonstrated 2 lymph nodes at the peripancreatic and paraaortic regions. Right inguinal orchiectomy was done and the pathologic examination revealed as epidermoid cyst. Patient was discharged from the hospital without any complication and no additional therapy was recommended. At the first year of follow up, there was no problem with the patient and intraabdominal lymph nodes were revealed as the same.

Key words: epidermoid cyst, benign testicular masses, orchiectomy

TESTİKÜLER EPIDERMİD KİST: OLGU SUNUMU VE LİTERATÜRÜN GÖZDEN GEÇİRİLMESİ

ÖZET

Epidermoid kistler orşiektomi materyallerinin%1 ile% 2'sini oluşturmakta ve testis tümörleri gibi soliter kitleler olarak palpe edilmektedirler. Bunlar selim lezyonlar olup testis koruyucu yaklaşım gibi konservatif tedavilerin eğer mümkünse orşiektomiye tercih edilmesi gereken durumlardır. Bugüne kadar lokal nüks veya metastaz bildirilmemiştir. Burada kliniğimize ağrısız sağ testiküler kitle ile başvuran 26 yaşında bir erkek hastayı sunmaktayız. Renkli doppler ultrasonografide 2 yuvarlak parankimal lezyonun eşlik ettiği büyük bir testis saptanmıştır. Serum testiküler germ hücre tümör belirteçleri normal olarak değerlendirilmiştir. Batın tomografisinde peripancreatik ve paraaortik alanda 2 adet lenf nodu saptanmıştır. Hastaya sağ inguinal orşiektomi yapılmış ve patolojik değerlendirmesi epidermoid kist olarak gelmiştir. Sorunsuz biçimde taburcu edilen hastaya ek tedavi önerilmemiştir. Birinci yılın sonunda yapılan değerlendirmede hasta ile ilgili problem saptanmamış, batın içindeki lenf nodlarının da aynı kaldığı görülmüştür.

Anahtar sözcükler: epidermoid kist, selim testiküler kitleler, orşiektomi

Introduction

In male population, benign intrascrotal lesions are a common finding. Most of them occur in paratesticular tissue and are cystic in nature. Unlike from testicular lesions, of those 95% are malignant, paratesticular lesions are more likely benign. Benign intrascrotal lesions can be classified in to two main group as testicular and paratesticular. Most common benign testicular lesions are; tunica albuginea cyst, testicular simple cyst, epidermoid cyst,

tubular ectasia of rete testis, intratesticular varicocele, adrenal rest tumor and splenogonadal fusion. Epidermoid cysts which is the main subject of this article account for approximately 1 to 2% of all orchiectomy masses. (1,2) Epidermoid cysts are benign lesions without malignant potential and if possible conservative treatment such as enucleation is generally preferred over orchiectomy. (3) No cases of local recurrence or metastases have been reported. (4) Here in we report a man with a right testicular mass which revealed as tumor and inguinal orchiectomy was performed.

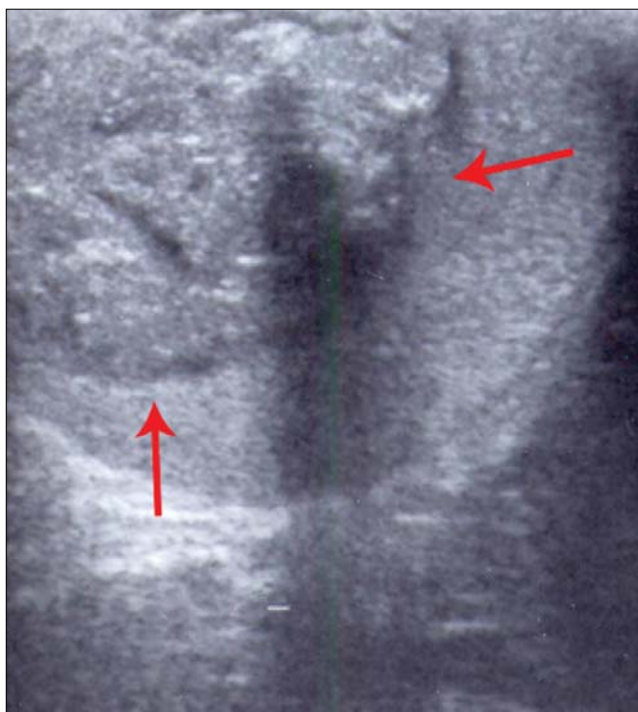


Figure 1. Ultrasonographic appearance of the testis and the mass. Red arrows show the intraparenchymal mass with hypoechoic center.

Presentation of case

a 26 year old man came to our clinic with 1 week history of a painless right testicular mass noticed on self- examination. Physical examination confirmed a large testicular mass. Color- doppler ultrasound findings demonstrated a large right testis with 2 round well defined intraparenchymal lesions diameter of 37 x 35 mm and 20 x 18 mm with hypoechoic centers. There was no comment about blood supply of the lesions and ultrasonography revealed them as testicular masses (Figure 1). Serum alfa- fetoprotein, beta- human chorionic gonadotropin and lactate dehydrogenase levels were normal. Chest computed tomography was also normal. Abdominal computed tomography of the patient demonstrated 2 lymph nodes at the peripancreatic and paraaortic regions with diameters of 16 x 10 mm and 16 x 12 mm. A right inguinal orchiectomy was recommended to the patient giving information about these lesions accepted as malignant unless the opposite decision was confirmed with pathologic examination.

Right inguinal orchiectomy was performed. The masses were 45 mm and 25 mm, cystic with yellow hard necrotic contents (Figure 2). Pathologic examination revealed stratified squamous epithelium with keratinization in the lesion without intratubuler germ cell neoplasia or teratomatous components. Pathologic diagnosis was epidermoid cyst (Figure 3). Patient

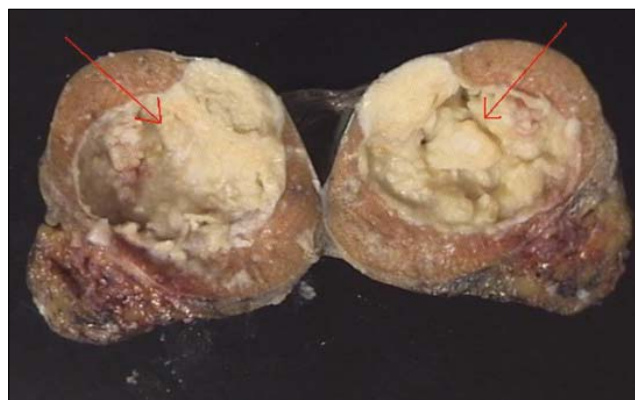


Figure 2: Epidermoid cyst containing friable, yellow- white keratinous material (red arrows).

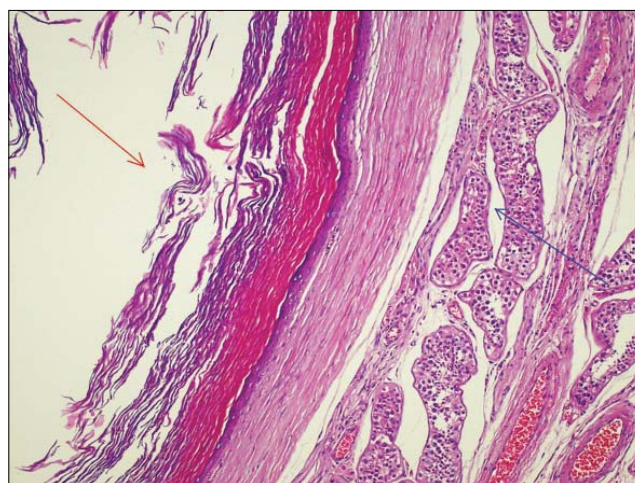


Figure 3: Cyst is lined by a thin, compressed stratified squamous epithelium, filled with keratin (red arrow) and surrounded by intact seminiferous tubules (blue arrow). (H&E, X 100)

was discharged from hospital without complication and no additional therapy was recommended.

At the first year of follow up, there was no problem with the patient and intraabdominal lymph nodes were revealed as the same.

Discussion

Epidermoid cyst of the testis accounts for approximately 1% of adult and 3% of pediatric testicular tumors. It occurs in patients from early childhood to old age but most patients are between 10 and 40 years old. (5) It typically presents as a painless testicular enlargement or may be found incidentally negative. Ther different in size but are most commonly 1 to 3 cm in diameter and bilateral epidermoid cysts are rare. (6) These solid intratesticular lesions always require further evaluation and ultrasound is a necessary part of the investigation. Ultrasound findings vary with the maturation of cyst, compactness and

the quality of keratin in the cyst. It demonstrates a well ovoid circumscribed lesion with variable echogenicity. There are several ultrasound appearances have been described for epidermoid cysts. These images can be seen as; a target or echogenic halo, a mass with a rim as the classic onion ring pattern and consisting of concentric rings of hyperechogenicity or hypoechogenicity. This ring pattern is considered as a characteristic of an epidermoid cyst and it corresponds to its natural evolution (1,7). Also as an important sign, there is no blood flow in the cyst on color-doppler ultrasound. These features including negative tumor markers, onion ring configuration, and lesion avascularity on the doppler ultrasonography are also important for differentiation of epidermoid cyst from other germ cell tumors. (6) Magnetic resonance imaging may be helpful for characterizing a fatty component of an epidermoid cyst (1).

Histologically epidermoid cysts are cystic cavities that contain exfoliated keratinized epithelium and are lined by stratified squamous epithelium. Price defined certain criteria as; 1) Lesion is within the testicular parenchyma, 2) Cyst contains keratinized debris or amorphous material with cleft-like spaces, 3) Cyst wall consists of fibrous tissue with an inner lining of squamous epithelium and 4) Teratomatous elements are not present in the cyst wall of the adjacent parenchyma (8).

There is no consensus about the histogenesis of epidermoid cysts, in the past it was suggested as squamous metaplasia of the rete testis or seminiferous epithelium but today they represent as a monodermal and/or unilateral development of a teratoma. These cysts are of germ cell origin (6). To date there have been no reported cases of recurrence or metastases of an epidermoid cyst. But Woo et al reported a case of seminoma development following conservative treatment of testicular epidermoid cyst at the same testis after 5 years from the first operation. (2) Review of the studies yielded no evidence of concurrent testicular

malignancy and although it is conceivable that the secondary lesion was originally overlooked,, it is unlikely due to length of time between two events. It may be unreasonable to recommend periodic follow up of these lesions because epidermoid cyst of testis exhibits uniformly benign clinical behavior and testis sparing surgery, when possible, appears to be a reasonable and safe treatment option (2,3).

Passman et al also reviewed non-germ cell testicular lesions at their institute and concluded that testis sparing surgery might be possible if there is significant suspicion of a benign lesion. According to their results testis sparing surgery was feasible in highly selected cases (9).

Conclusion

In our case we accepted these lesions as malignant according to the ultrasonographic description and lymph nodes in the abdomen so performed an inguinal orchiectomy. But due to the number and dimensions of the lesions, testis sparing surgery was not suitable for this patient even if the diagnosis was epidermoid cyst or another benign intratesticular lesion. In such cases when the diagnosis is uncertain but a benign lesion such as epidermoid cyst is suspected, surgery should be performed through an inguinal incision with the control of the cord. The mass can be explored and send for histological diagnosis. When a benign lesion is encountered, testis sparing surgery should be performed if suitable. In our daily urology practice we must not consider all the testicular masses as malignant and also think about the possibility of benign lesions even if the incidence is low. This point of view may avoid redundant orchiectomies.

Consent

Written informed consent was obtained from the patient for publication of this case report and accompanying pictures.

Conflict of Interest Statement

There was no conflict of interest with this case report.

References

1. Langer JE, Ramchandani P, Siegelman ES: Epidermoid cysts of the testicle: sonographic and MR imaging features. *Am J Roentgenol*, 1999; 173: 1295-1299.
2. Woo LL, Curtis MR, Cohen MB, Sandlow JL: Development of seminoma following conservative treatment of testicular epidermoid Cyst. *J. Urol*, 2001; 165: 1635- 1636.
3. Eisenmenger M, Lang S, Donner G: Epidermoid cyst of the testis: organ- preserving surgery following diagnosis by ultrasonography. *Br. J Urol*, 1993; 72: 955 -957.
4. Malek RS, Rosen JS, Farrow GM: Epidermoid cyst of the testis: a critical analysis. *Br. J Urol*, 1986; 58: 55 -59.
5. Umar SA, MacLennan GT: Epidermoid Cyst of Testis. *J Urol*, 2008; 180: 335.
6. Rubenstein RA, Dogra VS, Seftel AD, Resnick MI: Benign intrascrotal lesions. *J. Urol*, 2004; 171: 1765-1772.
7. Dogra VS, Gottlieb RH, Rubens DJ, Liao L: Benign intratesticular cystic lesions: US features. *Radiographics*, 2001; 21: 273-281.
8. Price EB: Epidermoid cysts of the testis: a clinical pathologic analysis of 69 cases from the testicular tumor registry. *J Urol*, 1969; 102: 708- 713.
9. Passman C, Urban D, Klemm K, Lockhart M, Kenney P, Kolettis P: Testicular lesions other than germ cell tumours: Feasibility of testis sparing surgery. *BJU Int*, 2009; 103(4): 488-491.