

# Gallbladder Duplication: A Rare Case Treated Laparoscopically

Tuncer Babür<sup>1</sup>, Emel Özveri<sup>1</sup>, Metin Ertem<sup>2</sup>

<sup>1</sup>Özel Acıbadem Kozyatağı Hastanesi, Genel Cerrahi, İstanbul, Türkiye  
<sup>2</sup>Cerrahpaşa Tıp Fakültesi, Genel Cerrahi, İstanbul, Türkiye

Tuncer Babür, Op. Dr.  
Emel Özveri, Op. Dr.  
Metin Ertem, Prof. Dr.

**Correspondence:**

Op. Dr. Tuncer Babür  
Özel Acıbadem Kozyatağı Hastanesi, Genel Cerrahi, İstanbul, Türkiye  
**Phone:** +90 216 571 42 53  
**E-mail:** tuncerbabur@yahoo.com

**Received :** April 16, 2018  
**Revised :** October 11, 2018  
**Accepted :** October 14, 2018

## ABSTRACT

Gallbladder duplication is a rare congenital malformation. Predicting and identifying the presence of this anomaly and other anatomical variations is important to avoid unwelcome surprises. Preoperative diagnosis is critical for planned surgery and prevention of possible complications. When bile duct anomalies are suspected, cholangiography during the operation has a critical importance in terms of prevention of complications. Laparoscopic removal of both gallbladders with intraoperative cholangiography seems to be the appropriate treatment of gallbladder duplication.

**Keywords:** Gallbladder duplication, bile duct anomaly, cholangiography, laparoscopy

## SAFRA KESESİ DUPLİKASYONU: LAPAROSKOPIK OLARAK TEDAVİ EDİLEN NADİR BİR OLGU

### ÖZET

Safra kesesi duplikasyonu nadir görülen bir konjenital malformasyondur. Bu anomali ve diğer anatomik varyasyonların varlığını tahmin etmek ve tanımlamak, istenmeyen sürprizlerden kaçınmak için önemlidir. Ameliyat öncesi tanı, planlı cerrahi ve olası komplikasyonların önlenmesi için kritik öneme sahiptir. Safra kanalı anomalilerinden şüphelenildiğinde, operasyon sırasında kolanjiyografi komplikasyonların önlenmesi açısından kritik öneme sahiptir. Her iki safra kesesinin intraoperatif kolanjiyografi ile laparoskopik olarak alınması safra kesesi duplikasyonunun uygun tedavisi gibi görünmektedir.

**Anahtar sözcükler:** Safra kesesi duplikasyonu, safra yolu anomalisi, kolanjiyografi, laparoskopi

**G**allbladder duplication is a rare congenital anomaly that occurs during embryogenesis in the fifth and sixth weeks of pregnancy (1). Frequency is estimated to be 0.02% via autopsy series and 0.03% via radiological imaging (2). This malformation is more common in women. The presence of a double cystic duct is associated with double gall bladder in over 80% of cases (3). Congenital malformations of the gallbladder, bile ducts and veins are more common.

Most anatomical variations are inside the "Calot triangle". Therefore, dissection of this region should be performed with utmost care. These anatomical variations may not cause any clinical findings. These variations are important because they can cause uncertainty in the identification of anatomical structures for the surgeon and may lead to problems during surgery. Surgery is not required for symptom-free gallbladder duplication (4). Operation is required when it contains stones or develops

inflammation. In this case report, we discuss a case of symptomatic gallbladder duplication and double-cystic duct treated with laparoscopic cholecystectomy in the light of literature.

## Case

A 47-year-old woman was admitted to our clinic with dyspepsia and pain in her back and abdomen. She had intermittent right upper quadrant abdominal pain with occasional nausea and vomiting. She had no history of jaundice or fever. She stated that her complaints had been present for 15 days. When her anamnesis and family history were examined, no notable traits were found other than a history of cesarean section. Physical examination revealed a soft abdomen with no palpable mass, but sensitivity was observed in the right upper quadrant. Ultrasonography (USG) revealed calculi in her gallbladder. Laboratory results including complete blood count, liver function tests, bilirubin and tumor markers showed no abnormalities. The patient was admitted for laparoscopic cholecystectomy. Informed consent was obtained after explaining the surgical procedure and possible complications. Then the patient was operated laparoscopically. During the dissection of Calot's triangle, it was considered that a double cystic duct could be present (Figure 1).

One of the cystic ducts was catheterized and cholangiography was performed during the operation (Figure 2).

Cholangiography revealed that the common bile duct and hepatic ducts were normally filled, and the passage of radiopaque material into the duodenum was observed. Thus, it was concluded that the patient had a double cystic duct opening to the common bile duct (Figure 3).

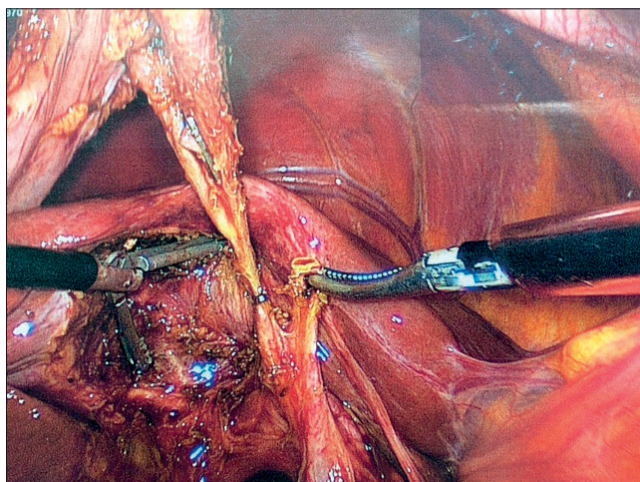


Figure 1. Double cystic duct

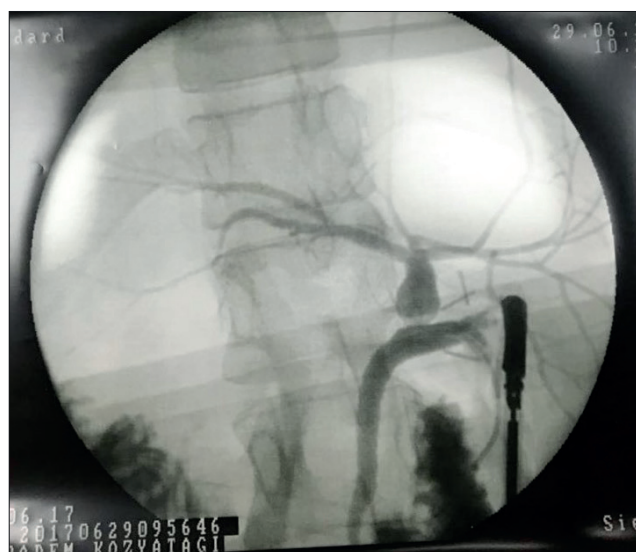

Figure 2. Cholangiography during surgery

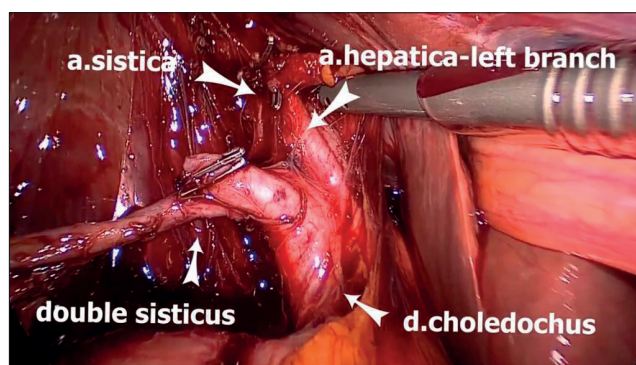


Figure 3. Anatomic Structures

Both cystic ducts and cystic arteries were clipped and cut. Retrograde dissection and separation of the gallbladder were performed and cholecystectomy was completed. The operation was finalized by placing a drain into the subhepatic area. When the specimen was examined, the presence of double cystic duct and double gall bladder was confirmed (Figure 4,5).

The patient had two separate gallbladders with separate cystic ducts. The bladders were adherent to each other and shared a common wall on one side. One of the gallbladders was smaller. It was observed that the gallstones were inside the larger gallbladder.

The pathology report also indicated gallbladder and cystic duct duplication. The patient was discharged without any complications on post-op day 3.

The patient provided informed consent for the publication of the clinical case as a case report.

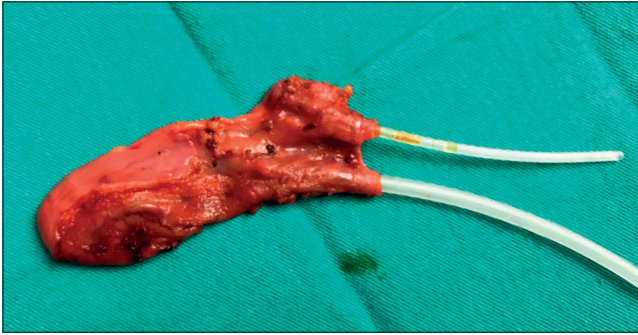


Figure 4. Appearance

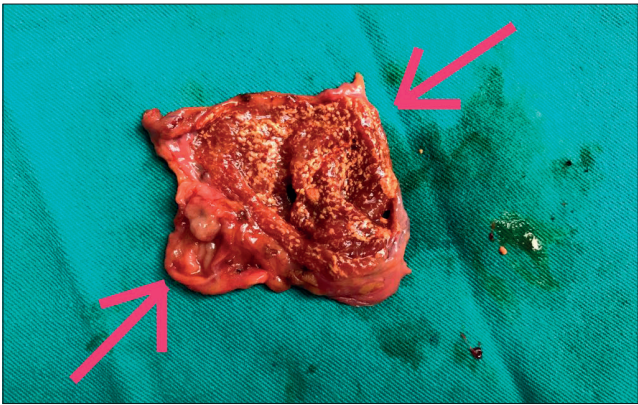


Figure 5. Appearance

## Discussion

Gallbladder duplication is a rare congenital anomaly and occurs in approximately one of 4000 births (5). It is important to detect anatomical variations before gallbladder dissection surgery to prevent possible complications and avoid the possibility of overlooking the removal of the additional gallbladder (6). Duplication of the gallbladder may be asymptomatic as well as symptomatic. Surgical procedures are not required for asymptomatic gallbladder duplications (4). In most symptomatic cases, stones and infections were found. In our case, stones were detected via USG.

Congenital anomalies of the gallbladder are classified by Boyden et. al. (5). According to the Boyden classification, there are two main types of gallbladder duplication:

- Type 1 (Vesica fellea divisa): Includes bilobed gallbladder and one cystic duct.

- Type 2 (Vesica fellea duplex): True gallbladder duplication. It includes two gallbladders and two cystic ducts.

Our case is a – Type 2 - true gallbladder duplication. Bladders share a common wall (H type).

Gallbladder duplication can be diagnosed via USG but USG may not give sufficient anatomical information. In suspected cases, endoscopic retrograde cholangiopancreatography (ERCP) and percutaneous transhepatic cholangiography (PTC) may be helpful but these methods are rarely used since they are invasive. CT is one of the diagnostic methods. Cholecystography and scintigraphy may be partially beneficial but are not routinely used. As a noninvasive method, magnetic resonance cholangiopancreatography (MRCP) should be accepted as a standard in suspected cases of bile duct anomalies (6-8).

In our case, only USG and biochemical analysis results were examined before the operation. Since no suspicious anatomic findings were detected in USG, MRCP was not ordered.

When bile duct anomalies are suspected during laparoscopic cholecystectomy, intraoperative cholangiography is recommended in order to minimize the risk of accidental damage and to reveal the structure of the biliary system (7,8). In our case, after suspicion of the double cystic duct, laparoscopic cholangiography was performed and cholecystectomy was performed safely after revealing the anatomy of the bile ducts.

Gallbladder diverticulum, choledochal cyst, Phrygian cap, bend of the gallbladder, focal adenomyomatosis, intraperitoneal bands and pericholecystic fluid are included in the differential diagnosis of gallbladder duplication (7, 9).

While some authors suggest the implementation of open surgery to prevent the risk of overlooking the diagnosis; successful treatments of gallbladder duplication via laparoscopic cholecystectomy are also reported in the literature (7). In our case, the operation was also performed laparoscopically and without any complications. Intraoperative cholangiography seems to be an appropriate method to avoid complications when there is suspicion of variation (9,10). In our case, the anatomy of the bile ducts was revealed via per-operative laparoscopic cholangiography.

## Conclusions

Gallbladder duplication is a rare congenital anomaly that requires special attention. Preoperative diagnosis has a critical importance in terms of surgery plans and prevention of possible complications. USG is the first-choice imaging technique when gallbladder disease is suspected. MRCP is a precious noninvasive imaging method that can

reveal biliary anomalies. However, it is known that MCRP may be insufficient in some cases. It should always be kept in mind that –as in our case- anomalies and variations may be encountered during surgery, and that pre-operative cholangiography may be required to identify these anomalies and variations.

## References

1. Causey MW, Miller S, Fernelius CA, Burgess JR, Brown TA, Newton C. Gallbladder duplication: evaluation, treatment, and classification. *Journal of pediatric surgery* 2010;45:443-6. [\[CrossRef\]](#)
2. Haubrich WS, Schaffner F, Berk JE, Bockus HL. *Bockus gastroenterology*: WB Saunders Co; 1995.
3. Huston TL, Dakin GF. Double cystic duct. *Canadian Journal of Surgery* 2008;51(1):E9-E10.
4. Puneet M, Agarwal S, Singh S, Khanna A. Double gallbladder. *The Internet Journal of Gastroenterology* 2006;4.
5. Boyden EA. The accessory gall-bladder—an embryological and comparative study of aberrant biliary vesicles occurring in man and the domestic mammals. *Developmental Dynamics* 1926;38:177-231. [\[CrossRef\]](#)
6. Mazziotti S, Minutoli F, Blandino A, Vinci S, Salamone I, Gaeta M. Gallbladder duplication: MR cholangiography demonstration. *Abdominal imaging* 2001;26:287-9. [\[CrossRef\]](#)
7. Al Rawahi A, Al Azri Y, Al Jabri S, Alfadli A, Al Aghbari S. Successful laparoscopic management of duplicate gallbladder: A case report and review of literature. *International journal of surgery case reports* 2016;21:142-6. [\[CrossRef\]](#)
8. Gorecki PJ, Andrei VE, Musacchio T, Schein M. Double gallbladder originating from left hepatic duct: a case report and review of literature. *JSL: Journal of the Society of Laparoendoscopic Surgeons* 1998;2:337.
9. Desolneux G, Mucci S, Lebigot J, Arnaud J, Hamy A. Duplication of the gallbladder. A case report. *Gastroenterology research and practice* 2009;2009. [\[CrossRef\]](#)
10. Nursal TZ, Ulasan S, Tercan F, Yildirim S, Tarim A, Noyan T, et al. Laparoscopic management of gallbladder duplication. *International surgery* 2007;92:195-7.

## Declarations

There was no conflict of interest and no financial support was received. Written informed consent was obtained from the patient for publication of this Case report and any accompanying images. A copy of the written consent is available for review by the Editor-in-Chief of this journal.