

Transcatheter Closure of a Muscular Ventricular Septal Defect By Amplatzer Ductal Occluder II

Alpay Çeliker¹, Fatih Atik²

¹Acıbadem University School of Medicine, Department of Pediatric Cardiology, Istanbul, Turkey

²Ahi Evren Hospital of Thoracic and Cardiovascular Surgery, Pediatric Cardiology Unit, Trabzon, Turkey

ABSTRACT

Ventricular septal defect has been targeted as a defect to close with transcatheter methods. In recent years with the advent of new devices percutaneous closure of ventricular septal defect has been used in many centers with encouraging results. Introduction of Amplatzer occluder devices has been resulted in increase the number of implants in recent years. Beside this, a few devices can be used for transcatheter closure of muscular ventricular septal defects. We report a successful transcatheter closure of muscular outlet ventricular septal defect in a 4 years of age child with Amplatzer Ductal Occluder II.

Key words: muscular ventricular septal defect, transcatheter closure, amplatzer duct occluder II

MÜSKÜLER VENTRİKÜLER SEPTAL DEFEKTİN AMPLATZER DUKTAL OKLÜDER II İLE TRANSKATETER KAPATILMASI

ÖZET

Ventriküler septal defektler transkateter tedavide kapatılması gereken bir defekt olarak görülmektedir. Son yıllarda yeni cihazların bulunması ile birçok merkezde ventriküler septal defektlerin perkütan kapatılması cesaretlendiren sonuçlarla uygulanmaktadır. Amplatzer oklüder sistemlerin son yıllarda kullanılmaya başlaması ile birlikte implantasyon sayılarında artma olmuştur. Bunun yanısıra, müsküler ventriküler septal defektlerin kapatılmasında birkaç cihaz kullanılabilir. Bu yazıda 4 yaşında bir çocukta müsküler outlet ventriküler septal defektin Amplatzer Duktus Oklüder II ile başarılı bir şekilde kapatılmasını bildirmek istedik.

Anahtar sözcükler: müsküler ventriküler septal defekt, transkateter kapatma, amplatzer duktus oklüder II

Ventricular septal defect accounts for approximately 30% of all congenital heart disease ; its prevalence is estimated at 1.17 per 1000 births and has increased recently because of improved detection (1). Although many of these defects are small and close spontaneously (2), the larger defects often persist to cause significant shunt and pulmonary arterial hypertension. Since Porstmann et al (3) reported the first transcatheter closure of a patent ductus arteriosus in 1967, several interventional techniques have been developed to treat various intracardiac defects. Ventricular septal defect had also been targeted as the defect to close with a device several years ago

(4,5). In recent years, new devices and refinement of techniques, a number of reports on percutaneous closure of ventricular septal defect have been published with encouraging results. Percutaneous transcatheter closure of muscular ventricular septal defect was first reported by Lock et al (4). Introduction of Amplatzer muscular ventricular septal defect occluder device has been resulted in increase the number of implants for ten years (6,7). We report a successful transcatheter closure of muscular outlet ventricular septal defect in a 4 years of age child with Amplatzer Ductal Occluder II.

Case report

Four years age boy, referred to our hospital who has pansystolic murmur and a history of recurrent lower respiratory tract infections. Clinically he had poor weight gain, signs of left ventricular volume overload, grade 3/6 pansystolic murmur in left lower sternal edge. Electrocardiogram showed sinus rhythm with left QRS axis deviation and mild left ventricular hypertrophy. Chest radiograph showed cardiomegaly with increased pulmonary blood flow. Echocardiography showed situs solitus, levocardia, a four mm muscular outlet ventricular septal defect with left to right shunting on color flow doppler. The distance of the ventricular septal defect rim to aortic and atrioventricular valves was 12 and 10 mm respectively (Figure 1). He had minimal aortic, mitral and tricuspid valve regurgitation and the signs of mild pulmonary arterial hypertension.

The patient then underwent complete right and left heart catheterization with continuous transesophageal echocardiography guidance under general anesthesia, which confirmed the exact location and the size of the defect and hemodynamic status including pulmonary to systemic flow ratio and pulmonary vascular resistance. Pulmonary artery pressure was 40/32 mean of 35 mmHg when the aortic pressure 85/68 mean of 78 mm Hg. QP/QS ratio was 1.3 and RP/RS ratio was 26,1%. Although the patient was symptomatic, and there was the signs of pulmonary hypertension we decided to perform transcatheter ventricular septal defect closure. Written informed consent was obtained from the parents.

Procedure

Transcatheter closure was performed under general anesthesia. Left ventricular angiography was performed in the long-axis view, and the size of the defect at the left ventricular surface was measured in diastole (Figure 1). The ventricular septal defect was crossed from the left to right using a 5 F cut pigtail catheter and a 0.035" glide guide-wire. The wire was then guided to the left pulmonary artery, and the catheter advanced over the wire through the ventricular septal defect. The guidewire was exchanged for a noodle wire, which was snared out from the right femoral vein, thus establishing a continuous arteriovenous loop. Over this wire, 5F Amplatzer Duct Occluder II Occluder Device Delivery System was advanced into the left ventricle. Then, a Amplatzer PDA2-05-06 device (AGA Medical Corporation, Golden Valley, MN) was used to close the defect. The device (waist 5 mm, length 6 mm and disc diameters 11 mm each) attached to its delivery system was advanced through the sheath to the left

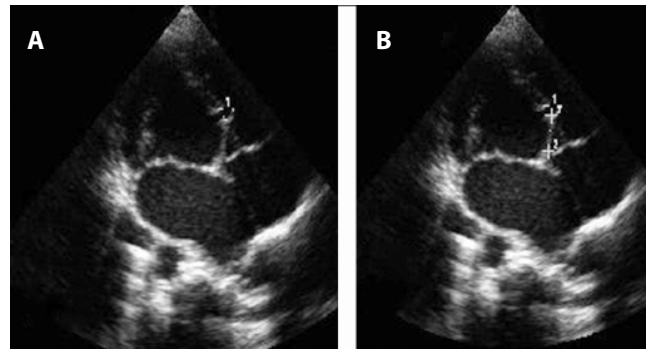


Figure 1. Transthoracic Echocardiography. Four chamber view demonstrated a 4 mm muscular ventricular septal defect (A); the distance between the superior rim of ventricular septal defect and AV valves was 11,4 mm (B).

ventricle. The distal disc was then extruded and pulled with the long sheath into the left ventricular surface of the defect. Left ventricular angiogram was repeated beside the transesophageal echocardiographic examination. While maintaining tension on the delivery cable, the proximal disc was also deployed (Figure 2A-E). Left ventriculogram and transesophageal echocardiography were revealed that there was no shunt and the disks were in appropriate side of the septum. After confirming that there was no impingement on either valve and no significant residual shunt, the device was released (Figure 2F). A repeat left ventricular angiogram showed no residual shunt across the ventricular septal defect. The total fluoroscopy time was 15 min, and the procedure time was 76 min. After 24 hours, repeat echocardiography showed that the device was in situ without any residual shunt. The patient was discharged on 5 mg/kg daily aspirin. At follow-up of 42 months, the patient is asymptomatic with no residual shunt and device related problem.

Discussion

This report describes an unusual use of Amplatzer Duct Occluder II device in a child with high muscular ventricular septal defect. Surgical closure of muscular ventricular septal defect still poses a significant surgical challenge. Various different surgical approaches have been proposed; however, overall morbidity remain higher than with isolated perimembranous ventricular septal defects (8,9). Amplatzer muscular ventricular septal defect device has gained worldwide acceptance from the first used time and there are several reports describing effectiveness and safety of this device (6,7). Holzer and friends (10) reported successful results in 70 patients with hemodynamically significant muscular ventricular septal defects with percutaneous approach. They experienced major complications in eight patients. A lower weight of the patient at the

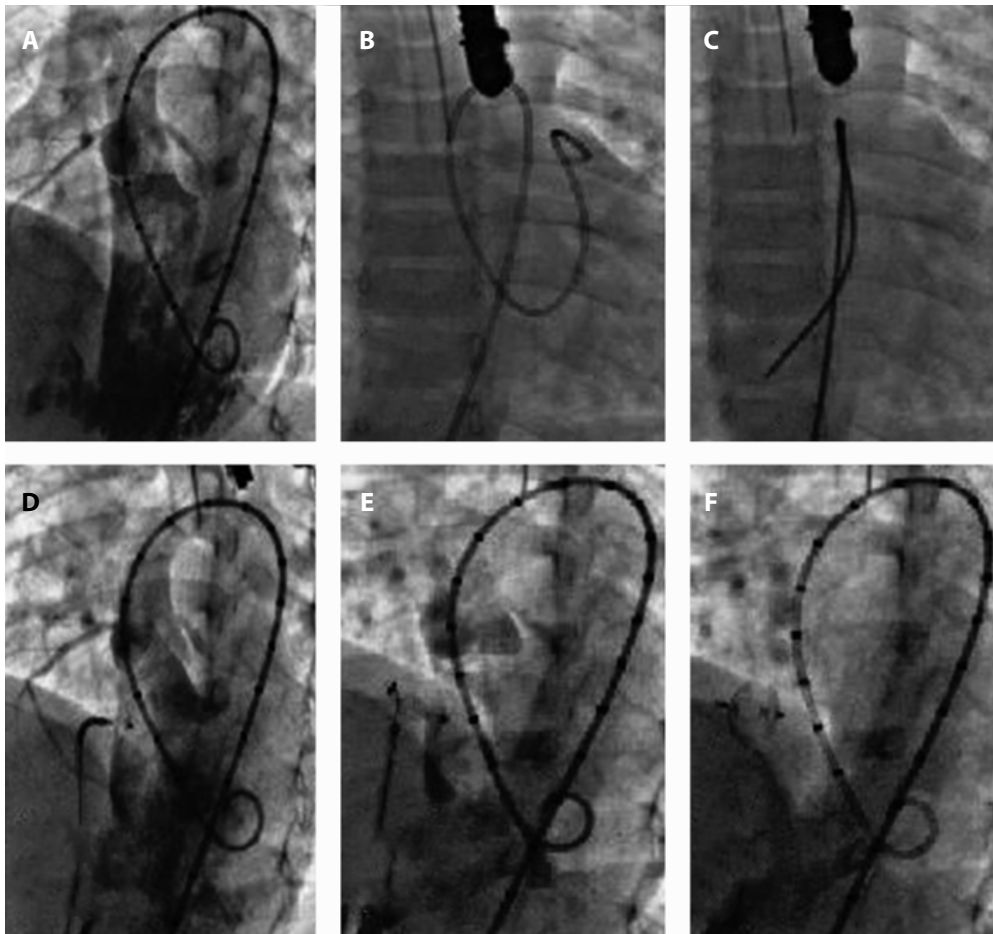


Figure 2. Transcatheter Closure. Four chamber angiogram revealed high located muscular ventricular septal defect (A); the cut-pigtail catheter inside the pulmonary artery (B); arteriovenous loop creation (C); angiogram after the distal disk opened (D); angiogram after the distal and proximal disk opened (E); position of the device after release (F).

time of the procedure significantly correlated with an increased risk of procedure- or device-related complications (10). In addition to the many advantages, the transcatheter treatment offers a shorter hospital stay. In patients with superiorly located muscular ventricular septal defect, one should be very careful for tricuspid valve apparatus and device interaction. In one previous study, one temporary tricuspid valve incompetence, which was disappeared in 24 hours (11). This finding may be explained by tricuspid valve septal leaflet chorda trapping by the right retention disk. Surgery was performed in one patient with superiorly located muscular ventricular septal defect in this study group to prevent permanent tricuspid valve damage. The postulated mechanisms for this complication may have been long waist length and relatively stiff disks of muscular ventricular septal defect closure device. In present case, a 6 mm Amplatzer muscular ventricular septal defect occluder (waist 6 mm, length 7 mm and disk diameter 14 mm) would be appropriate. In that situation

a 6F sheath should be needed to use a relatively large device with more metal inside the heart. We used Amplatzer Duct Occluder II device, because of suitable feature for this highly located muscular ventricular septal defect.

The Amplatzer Duct Occluder II is a modification of the Amplatzer duct occluder I. There are no polyester patches and is made of fine Nitinol. The disks can swivel around the connecting waist adapting at different angles of PDA. The size of connecting waist ranges from 3 to 6 mm. The Amplatzer Duct Occluder II can be delivered via 4F to 5F low-profile braided and tapering sheath with flexible distal segment. The Amplatzer Duct Occluder II is not suitable for closure of PDAs >5.5 mm in diameter (12,13). The Amplatzer Duct Occluder II was manufactured to solve some problems of the Amplatzer duct occluder I. The most important feature of the Amplatzer Duct Occluder II is the very-low-profile disks, which can swivel around the connecting waist and adapt at different angles of PDA. The

Amplatzer Duct Occluder II can be implanted in small infants with the use of low-profile sheaths. Thanopoulos and friends (12) reported first experiences Amplatzer Duct Occluder II for PDA closure. The median age and weight of the patients were 3.2 years, 10.5 kg respectively. The mean PDA diameter was 3.6 ± 1.3 mm. Complete echocardiographic closure of the ductus at 1-month follow-up was observed in 96% patients.

Although the Amplatzer Duct Occluder II device are made to close the PDA, features; such as low profile, shape and the disk sizes; may be useful in cases with highly located muscular ventricular septal defect. In our case, the use of

Amplatzer Duct Occluder II device was uneventful and the defect was completely closed. The major disadvantage for the Amplatzer Duct Occluder II may be relatively late disappearance of flow through the device, since there is no fabric inside the disks. This disadvantage may restrict the its usage in large defects.

In conclusion, transcatheter device closure with Amplatzer Duct Occluder II device seems to be effective and safe in the treatment of high located muscular ventricular septal defects. Although short term result is encouraging, we do not know the long term effectivity of this device.

References

- Lewis DA, Loffredo CA, Corre-Villasenor A, Wilson PD, Martin GR. Descriptive epidemiology of membranous and muscular ventricular septal defects I the Baltimore-Washington infant study. *Cardiol Young* 1996; 6: 281-90.
- Shirali GS, Smith EO, Geva T. Quantitation of echocardiographic predictors of outcome in infants with isolated ventricular septal defect. *Am Heart J* 1995;130: 1228-35.
- Porstmann W, Wierny L, Warnke H. Der Verschluss des Ductus arteriosus persistens ohne Thoracotomie. *Thoraxchirurgies* 1967; 15: 199-203.
- Lock JE, Block PC, McKay RG, Baim DS, Keane JF. Transcatheter closure of ventricular septal defects. *Circulation* 1988; 78: 361-368.
- Bridges ND, Perry SB, Keane JE, et al. Preoperative transcatheter closure of congenital muscular ventricular septal defects. *N Engl J Med* 1991; 324: 1312-17.
- Thanopoulos BD, Tsaousis GS, Konstadopoulou GN, Zarayelyan AG. Transcatheter closure of muscular ventricular septal defect occluder: Initial clinical application in children. *J Am Coll Cardiol* 1999; 33: 1395-99.
- Hijazi ZM, Hakim F, Al-Fadley F, Abdelhamid J, Cao QL. Transcatheter closure of single muscular ventricular septal defects using the Amplatzer Muscular VSD Occluder: Initial results and technical considerations. *Cathet Cardiovasc Interv* 2000;49:167-72.
- Wollenek G, Wyse R, Sullivan I, Elliott M, de Leval M, Stark J. Closure of muscular ventricular septal defects through a left ventriculotomy. *Eur J Cardiothorac Surg* 1996;10:595-8.
- Stellin G, Padalino M, Milanese O, et al. Surgical closure of apical ventricular septal defects through a right ventricular apical infundibulotomy. *Ann Thorac Surg* 2000;69:597-601.
- Holzer R, Balzer D, Cao QL, Lock K, Hijazi ZM. Device closure of muscular ventricular septal defects using the Amplatzer muscular ventricular septal defect occluder. *J Am Coll Cardiol* 2004; 43: 1257-63.
- Celiker A, Ozkutlu S, Karagöz T, Erdoğan I, Ozer S, Aypar E. Device closure of congenital ventricular septal defects with Amplatzer devices: first experiences in Turkey. *Turk J Pediatr* 2008; 50: 106-13.
- Thanopoulos B, Eleftherakis N, Tzannos K, Stefanadis C. Transcatheter closure of the patent ductus arteriosus using the new Amplatzer duct occluder: initial clinical applications in children. *Am Heart J* 2008; 156:917.e1-917.e6.
- Thanopoulos BV, Tzannos KA, Eleftherakis N, Stefanadis C. Comparison and results of transcatheter closure of patent ductus arteriosus using the swivel-disk device versus plug occluder in children. *Am J Cardiol* 2008; 102: 486-90.