

# Treatment of Rectourethral Fistula by the York Mason Technique: Report of a Case

Merter Gülen<sup>1</sup>, Bedrettin Bülent Mentеш<sup>1</sup>, Sezai Leventođlu<sup>5</sup>, Beyhan Demirhan<sup>2</sup>, Bahattin Duru<sup>3</sup>, Mehmet Yörübulut<sup>4</sup>

<sup>1</sup>Acıbadem Ankara Hospital, General Surgery Department, Ankara, Turkey

<sup>2</sup>Acıbadem Ankara Hospital, Pathology Department, Ankara, Turkey

<sup>3</sup>Acıbadem Ankara Hospital, Department of Anesthesiology, Ankara, Turkey

<sup>4</sup>Acıbadem Ankara Hospital, Radiology Department, Ankara, Turkey

<sup>5</sup>Gazi University Faculty of Medicine, Department of Surgery Ankara, Turkey

## ABSTRACT

Rectourethral fistulas (RUFs) are uncommon, and they can be classified as congenital or acquired. Acquired RUFs result from surgical complications, pelvic irradiation or ablative treatments, trauma, chronic infection, or malignancy. Imperforate anus is a relatively common form of congenital anomaly in children. It occurs approximately one in every 5000 live births. It may be complicated by other congenital anomalies. We report a case of rectourethral fistula due to operations for imperforate anus and treated by the York Mason technique.

**Key words:** Rectourethral fistula, Imperforate anus, York Mason technique

## REKTOÜRETRAL FİSTÜL TEDAVİSİNDE YORK MASON TEKNİĐİ: OLGU SUNUMU

### ÖZET

Rektoüretral fistüller nadir görülür, ve kazanılmış veya konjenital olarak sınıflandırılabilirler. Kazanılmış rektoüretral fistüller; cerrahi komplikasyonlar, pelvik radyasyon veya ablatif tedaviler, travma, kronik enfeksiyon ya da malignite sonucu karşımıza çıkmaktadır. İmperfore anüs çocuklarda nispeten daha sık görülen konjenital bir anomalidir. Yaklaşık her 5000 canlı doğumda bir görülür. Diğer konjenital anomaliler ile birliktelik gösterebilir. Bu raporda imperfore anüs nedeniyle birçok operasyon geçirmiş hastada gelişen rektoüretral fistülün York Mason tekniđi ile onarımı sunulmuştur.

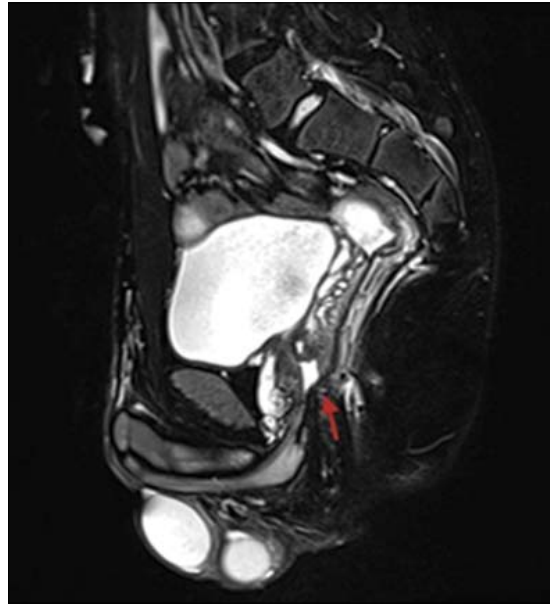
**Anahtar sözcükler:** Rektoüretral fistül, İmperfore anüs, York Mason tekniđi

## Introduction

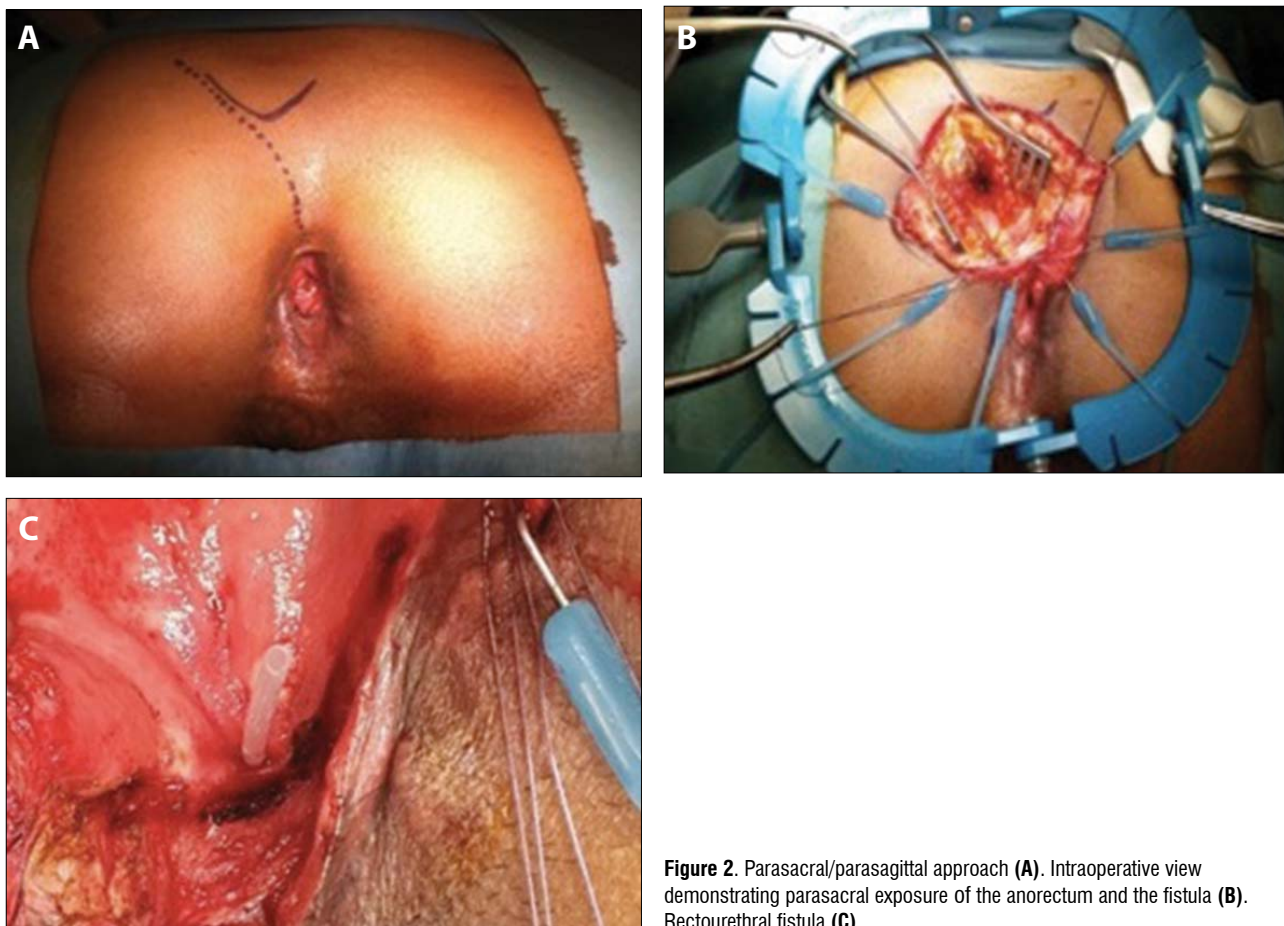
Fistulas of the urinary tract are caused by an abnormal communication between two epithelium-lined organs or vessels which are not usually in contact. They are associated with substantial physical and also psychologic distress. Several operative techniques/approaches have been proposed over the years, including the York-Mason approach, a transrectal, transsphinteric procedure offering a high success rate with low morbidity (1-2). We report a case of rectourethral fistula (RUF) treated by the York Mason technique.

## Report of a case

A 19-year-old male patient was referred to our hospital with the diagnoses of RUF and anal incontinence. As a newborn, he had undergone numerous operations for



**Figure 1.** MRI-T2 fat-sat sagittal image shows the rectourethral fistula tract (arrow).



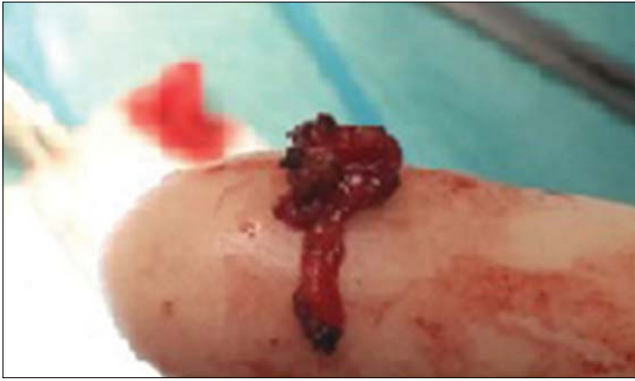**Figure 2.** Parasacral/parasagittal approach (A). Intraoperative view demonstrating parasacral exposure of the anorectum and the fistula (B). Rectourethral fistula (C).

imperforate anus. The symptoms (fecaluria and/or urine discharge from the anus) appeared after the operations performed for imperforated anus. In 2011, a colostomy was fashioned at another center for anal incontinence.

Proctologic examination revealed a patulous anus. Anal manometric study revealed low resting (RP) and squeeze pressures (SP), (RP:39 and SP: 95 cmH20). Pelvic contrast magnetic resonance imaging (MRI) also demonstrated the RUF (Figure 1). After preoperative preparations and consultations, the patient was operated on. RUF repair by the York Mason technique was performed. In prone jack-knife position, a parasacral/parasagittal approach was used (Figure 2A). The incision passed through the subcutaneous tissue until reaching the gluteus maximus muscle at its caudal end, the levator ani, and the external sphincter. Matched paired 3-0 polyglactin sutures were placed in the anal sphincter muscles before they were carefully incised. The placement of the matched sutures guarantees adequate reconstruction of the anus. The posterior wall of the inferior rectum was exposed and sectioned longitudinally to expose the anterior rectal wall (Figure 2B). At this point, the orifice of the fistulous tract was visualized (Figure 2C). We then proceeded to resect the

fistula tract and the surrounding inflammatory tissue with blunt and sharp dissection (Figure 3). The urethral defect was sutured with a single-layer of interrupted 4-0 polyglactin suture. Anterior rectal wall was then closed in single-layer of interrupted 2-0 polyglactin suture. The posterior rectal wall was closed with a continuous 2-0 polyglactin suture. Finally, the paired sutures placed at the beginning of the procedure were tied, thus allowing precise re-alignment of the muscle structures sectioned during access (internal sphincter, external sphincter, and levator ani). Sphincteroplasty with overlapping sphincter repairs were added. A subfascial drain was left in the subcutaneous layer and the skin was closed with polypropylene sutures and staples (Figure 4). A silicon urinary catheter was placed through the urethra into the bladder, and left in place for 8 weeks.

Pathologic examination revealed the fistulous tract with uroepithelium and fibromuscular tissue. The postoperative course was uneventful. Wound healing was perfect. His next hospitalization was planned 3-4 months later for the evaluation of anal continence, fistula healing, and possible colostomy closure.



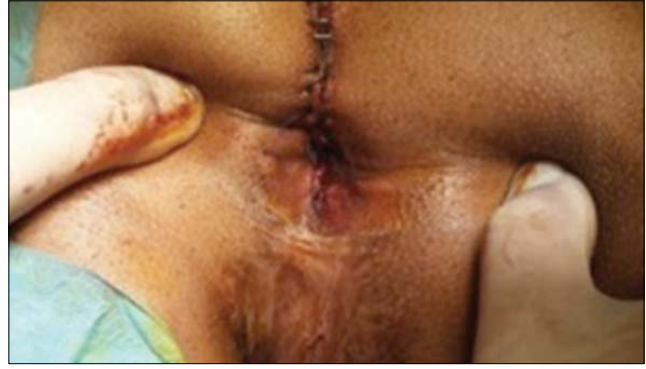**Figure 3.** The fistula tract

## Discussion

Injury to the urethra and to the sphincters are the two most dangerous complications of perineal procedures performed for imperforate anus in the neonate. The RUF persisting after a perineal procedure could be either iatrogenic or congenital that the surgeon has failed to recognize and close at the time of surgery. In low anorectal malformation (ARM) the fistula is mostly absent; thus, a fistula presenting after anoplasty for low ARM is likely to be an iatrogenic one. In our case, symptoms of RUF started after the operations for imperforated anus. Accordingly, it was assumed to be iatrogenic following surgery for anorectal malformation.

The presence of a RUF may be suspected when clinical signs and symptoms, such as urinary tract infections, fecaluria, hematuria, fever, nausea or vomiting, or even peritonitis and sepsis, emerge. Although the diagnosis of RUF can rely on clinical history and physical examination, the correct localization of the fistula tract may be difficult. Radiological and/or endoscopic methods, such as tomography, magnetic resonance imaging, urinary and retrograde urethrocytography, opaque enema, cystoscopy and/or rectosigmoidoscopy are usually necessary. The use of cystoscopy is essential in view of its high sensitivity (80 – 100%) (3). In our case, the localization of the fistula tract, and the relations between the rectum and urethra was confirmed by magnetic resonance imaging and cystoscopy.

Operative repair is the best treatment because conservative management with catheter drainage, bowel rest, and intravenous alimentation is usually ineffective (4,5). Some favorable results have been reported with the application of fibrin glue, endoscopic suturing, or fulguration of the fistulous tract, but reported experience is very limited (6). The surgical objectives in the management of the fistula are permanent separation of the urinary and fecal streams, prevention of urethral injury, and preservation of urinary and fecal continence.



**Figure 4.** Postoperative view following reconstruction of the anorectum

In addition to the technical aspects of the fistula repair, it is extremely important to understand the role of fecal and urinary diversion in the management of RUF. Successful repair of the fistula without a colostomy has been achieved by various investigators (7-10) who feel that a colostomy is necessary only in selected patients with a large defect, poor general condition, extensive trauma, or in hopeless cases. However, the majority of the available reports (11-15) favors that a double diversion (suprapubic and colostomy) is virtually mandatory for maximizing the chances for successful fistula repair. In our patient, colostomy was already present, and it will probably support successful healing.

Many techniques have been described for the treatment of RUF like transanal, perineal, abdominoperineal, perineal transsphincteric, or posterior sagittal pararectal approaches (3). The York Mason technique clearly combines the principles and features of its predecessor in an attempt to fulfill the objectives of permanent separation of the urinary and fecal streams, avoiding urethral injury, and preserving urinary and fecal continence. This approach facilitates maintaining a plane of dissection close to the rectal wall, thus, avoiding injury to the pelvic nerve plexus or urethra. The York-Mason technique, as exemplified in this report, provides perfect exposure of the RUF and a reliable suture repair. However, the parasacral approach and dissection require special expertise and experience in pelvic/perineal surgery.

On the basis of small number of cases, one cannot claim a standard technique for RUF. The treatment of fistula is very much individualized, and it depends on the cause, experience, and associated problems such as anal or urethral stricture. A protective colostomy may be useful for successful repair.

## References

1. Rovner ES. Urinary tract fistulae. In: Campbell-Walsh Urology. 9th ed. Philadelphia: WB Saunders Elsevier 2009; 2322-60.
2. Dal Moro F, Mancini M, Pinto F, Zanovello N, Bassi PF, Pagano F. Successful repair of iatrogenic rectourinary fistulas using the posterior sagittal transrectal approach (York-Mason): 15-year experience. *World J Surg* 2006;30:107-13.
3. Hanus T. Rectourethral fistulas. *Int Braz J Urol* 2002;28:338-45.
4. Bukowski TP, Chakrabarty A, Powell IJ, Frontera R, Perlmutter AD, Montie JE. Acquired rectourethral fistula: methods of repair. *J Urol* 1995;153:730-3.
5. Stephenson RA, Middleton RG. Repair of rectourinary fistulas using a posterior sagittal transanal transrectal (modified York-Mason) approach: an update. *J Urol* 1996;155: 1989-91.
6. Wilbert DM, Buess G, Bichler KH. Combined endoscopic closure of rectourethral fistula. *J Urol* 1996;155:256-8.
7. Culp OS, Calhoon HW: A variety of rectourethral fistula. Experiences with 20 cases. *J Urol* 1964 91:560-571.
8. Miller W: A successful repair of a recto-urethral fistula. *Br J Surg* 1977 64:869-871.
9. Fengler SA, Abcarian H: The York Mason approach to repair of iatrogenic rectourinary fistulae. *Am J Surg* 1997 73:213-217.
10. Henderson DJ, Middleton RG, Dahl DS, et al: Single stage repair of rectourinary fistula. *J Urol* 1981 125:592-593.
11. Chtourou M, Khalfallah T, Dahmoul H: Anterior anal approach in the management of urethral-rectal fistulas. *Prog Urol* 1997 7:640-642.
12. Tiptaft RC, Motson RW, Costello AJ, et al: Fistulae involving rectum and urethra: The place of Parks operation. *Br J Urol* 1983 55:711-715.
13. Kilpatrick FR, Thompson HR: Postoperative rectoprostatic fistula and closure by Kraske's approach. *Br J Urol* 1962 34:470-474.
14. Beneventi FA, Cassebaum WH: Rectal flap repair of prostaticorectal fistula. *Surg Gynecol Obstet* 1971 133:489-492.
15. al-Alim M, Kashmoula D, et al: Experience with 30 posttraumatic rectourethral fistulas: Presentation of posterior transsphincteric anterior rectal wall advancement. *J Urol* 1997 158:421-424.