

Outcome of Displaced Proximal Humerus Fractures Treated Surgically by Locking Plate- a Retrospective Case-Series Study

Emre Kaya¹, Mehmet Oguz Durakbasa²

¹ Department of Orthopaedics and Traumatology, Özel Çakmak Erdem Hospital, Istanbul, Turkey

² Department of Orthopaedics and Traumatology, Acıbadem Kozyatağı Hospital, Istanbul, Turkey

ABSTRACT

Objectives: To evaluate functional outcomes, radiographic findings and complications of displaced proximal humerus fractures (PHFs) treated surgically by osteosynthesis with locking plate (OLP), to determine unpredictable results after surgery and to suggest essential surgical tips and tricks.

Methods: Twenty-five patients were evaluated retrospectively. Constant shoulder score, ASES shoulder score and range of motion (ROM) were used to evaluate clinical outcome. Preoperative and final follow-up radiographs were used and humeral neck-shaft inclination angle described by Boileau and avascular necrosis (AVN) of the humeral head evaluated by Cruess classification were recorded to judge radiological outcome.

Results: Patients were 58(28-92) years old. The median Constant and ASES scores were 80(60-89) and 80(60-95) respectively. Neck-shaft inclination angle was 135(120-144) degrees at the final follow-up. 11 patients (44%) had complications. Major complications were AVN and varus malunion and both had a rate of 12% individually. Technical errors during surgery, mainly placing the plate high and screw-related complications, had adverse effect on AVN and varus malunion. Functional scores were not affected significantly by age, gender, AO and Neer fracture types and concomitant injuries. The clinical outcome has significantly become worse if varus malunion and/or AVN proceeded. Revision rate was 20% and its leading cause was AVN.

Conclusion: Age, gender, fracture type and additional fracture elsewhere did not affect clinical outcome significantly. OLP for PHFs had favorable radiological and clinical outcomes unless varus malunion and/or AVN of the humeral head proceeded postoperatively. To avoid the complication of screw cutout and varus; only the cortical bone and 2cm further were drilled and spongios bone allograft was used in case of comminution in the metaphysis and "strut" bone allograft was used in case of non-integrity in the medial metaphysis

Keywords: proximal humeral fracture; bone plate; orthopedic procedures; outcome assessment

ÖZET

Amaç: Kilitli plak ile osteosentez (OLP) ile cerrahi olarak tedavi edilen deplase proksimal humerus kırıklarının (PHF) fonksiyonel sonuçlarını, radyografik bulgularını ve komplikasyonlarını değerlendirmek, cerrahi sonrası öngörülemez sonuçları belirlemek ve temel cerrahi ipuçları ve püf noktaları önermek.

Yöntemler: Yirmi beş hasta retrospektif olarak değerlendirildi. Klinik sonuçları değerlendirmek için Constant omuz skoru, ASES omuz skoru ve eklem hareket açıklığı (EHA) kullanıldı. Ameliyat öncesi ve son takip radyografileri kullanıldı ve radyolojik sonucu değerlendirmek için Boileau tarafından tanımlanan humerus boyun-şaft eğim açısı ve Cruess sınıflamasına göre değerlendirilen humerus başı avasküler nekrozu (AVN) kaydedildi.

Bulgular: Hastalar 58(28-92) yaş arasındaydı. Ortanca Constant ve ASES skorları sırasıyla 80(60-89) ve 80(60-95) idi. Son takipte boyun-şaft inklinasyon açısı 135(120-144) derece idi. 11 hastada (%44) komplikasyon görüldü. Başlıca komplikasyonlar AVN ve varus malunionu idi ve her ikisi de ayrı ayrı %12'lik bir orana sahipti. Başta pate'in yükseğe yerleştirilmesi ve vidaya bağlı komplikasyonlar olmak üzere ameliyat sırasındaki teknik hatalar AVN ve varus malunionu olumsuz etkiledi. Fonksiyonel skorlar yaş, cinsiyet, AO ve Neer kırık tipleri ve eşlik eden yaralanmalardan önemli ölçüde etkilenmemiştir. Varus malunion ve/veya AVN ilerlediğinde klinik sonuç anlamlı derecede kötüleşmiştir. Revizyon oranı %20 idi ve bunun önde gelen nedeni AVN idi.

Sonuç: Yaş, cinsiyet, kırık tipi ve başka bir yerdeki ek kırık klinik sonuçları anlamlı olarak etkilememiştir. Ameliyat sonrası humerus başında varus malunionu ve/veya AVN gelişmediği sürece, PHF'ler için OLP olumlu radyolojik ve klinik sonuçlara sahipti. Vida kesilmesi ve varus komplikasyonundan kaçınmak için; sadece kortikal kemik ve 2 cm daha fazla delindi ve metafizde komünite durumunda spongios kemik allogrefti ve medial metafizde bütünlük olmaması durumunda "strut" kemik allogrefti kullanıldı.

Anahtar Kelimeler: proksimal humerus kırığı; kemik plağı; ortopedik prosedürler; sonuç değerlendirmesi

Emre KAYA

0000-0002-9493-8790

Mehmet Oguz DURAKBASA

0000-0002-5886-312X

Correspondence: Emre Kaya

Department of Orthopaedics and Traumatology,

Özel Çakmak Erdem Hospital,

Istanbul, Turkey

Phone: +90 536 680 09 34

E-mail: emrekaya0034@gmail.com

Received: 08.11.2023

Accepted: 07.05.2024

Surgical treatment options for proximal humerus fractures (PHFs) can be separated basically into two groups; osteosynthesis and arthroplasty. Although arthroplasty has become popular nowadays by the new designs- namely reverse shoulder arthroplasty- especially in the elderly people, osteosynthesis with locking plate (OLP) is still a reliable option for treating these fractures. Both treatment modalities are fraught with complications; on the OLP site, the the major ones being varus malunion, avascular necrosis (AVN), technical errors in surgery or late implant-related complications.^[1,2]

Varus malunion is attributed to osteoporotic bone and/or medial cortex comminution.^[1] Intramedullary cortical bone support^[3], medial calcar screws driven through the plate^[4], cement augmentation of humeral head screws^[5], double plating^[6] are defined to get rid of this complication. On the other hand, technical errors and/or AVN can lead to this complication as well and these major complications can happen in a vicious circle.

AVN of the humeral head in traumatic cases is related to the type of the fracture and type and timing of the surgery. Neer type 4 fractures and fracture-dislocations, open reduction and internal fixation and surgery performed after 48 hours are reported as risk factors.^[1,7]

Locking plates are preferred to conventional plates for the osteosynthesis of proximal humeral fractures because of less mechanical complications which was reported as 11% and 50% respectively.^[2] These mechanical complications are usually screw-related, namely screw perforation, screw cut-out, screw loosening, screw pull-out.^[2] Screw-related complications can be lowered by respect of technical tips and tricks while performing locking plates.

Thus, the purpose of this study is to evaluate functional outcomes, radiographic findings and complications of proximal humerus fractures (PHFs) treated surgically by osteosynthesis with locking plate (OLP) to determine unpredictable results after surgery and to suggest essential surgical tips and tricks. The hypothesis is that OLP has favorable results in PHF if surgical tips and tricks are performed and major complications are avoided.

Materials and Methods

The study retrospectively evaluated 25 patients who underwent OLP surgical treatment for PHFs between 2005 and 2011 at our clinic. Institutional Review Board (IRB) (E-62977267-771-209014806) was obtained from the ethics committee of Haydarpasa Numune training and research hospital before starting the study. All the surgeries were performed by a single surgeon who is specialized in shoulder surgery. The indication for surgery was based on Neer criteria^[8], namely angulation of the humeral head greater than 45 degrees and displacement of the fragments greater than 1 cm. The exclusion criteria were the cases under bone-maturity, minimal displaced fractures according to Neer classification, open fractures, pathologic fractures and isolated fractures of the humeral tubercles. The preoperative radiological examination consisted of true anteroposterior (AP) and axillary X-Ray and computerized tomography (CT) and 3-dimensional CT of the shoulder. Neer and AO classification were used for fracture classification.^[9] The patients were evaluated radiologically and clinically in the postoperative final follow-up. The criteria for radiological assessment were malunion which was depicted by the neck-shaft inclination angle defined by Boileau^[10] and avascular necrosis which was evaluated by Cruess classification^[11]. Boileau proposed that if inclination angle is <120 degree, it is a varus mal-union; if the inclination angle is >150 degree, it is a valgus malunion. Cruess classification delineates AVN stages as Stage 1: normal on the X-Ray, changes on magnetic resonance imaging (MRI), Stage 2: sclerotic changes in the humeral head where the sphericity of the humeral head is preserved, Stage 3: subchondral collapse or the sphericity of the humeral head is distorted, Stage 4: chondral collapse and osteochondritis dissecans, Stage 5: osteoarthritic changes in the glenoid fossa. Constant and ASES shoulder scores calculated at the final follow-up were used and ROM at the final follow-up was measured for clinical assessment.^[12,13]

Surgical Technique

The patients were positioned in beach chair position under general anesthesia. Anterior approach was performed. Cephalic vein was found and protected and the fracture site was exposed through the deltopectoral interval. If the fracture was a Neer 2-part fracture, it was directly accessed. If the fracture was a Neer 3-part or a 4-part

fracture or a fracture-dislocation, deltopectoral fascia was opened, long head of biceps tendon was found and suspended by a penrose drain. By opening the rotator interval, one can not only access the fractured tubercles but also by opening the tubercles as a book page expose the humeral head as well. Humeral head was reduced to anatomical position and was temporarily fixed with Kirschner (K) wires. The tubercles were reduced thereafter. Before the plate placement, two no2 vicryl sutures were passed through the upper holes of the plate and two through the holes prepared on the distal shaft of the humerus. The plate was placed just lateral to the long head of biceps tendon and approximately 1 cm below to the humeral head. The plate was stabilized proximally by K wires placed into the holes at the top of the plate. It was also fixed distally to the shaft of the humerus by a screw placed through the oval hole of the plate. Intra-operative imaging was used by taking 3 shots, namely true AP, AP in external rotation and AP in internal rotation, to determine that the plate and the screws were placed in appropriate height and length respectively. In order to prevent screw cut-out only the cortical bone and 2cm further were drilled and the gauge to measure the length of the screw was advanced till its advancement was blocked by the hard subchondral bone. The last distal screw of the proximal part of the plate was always used keenly in a fashion to support the inferomedial part of the humeral head to prevent further varus malalignment. no2 vicryl sutures which were formerly placed through the upper holes of the plate were passed into the tubercles, first through the bone and then through the rotator cuff in an over-and-over fashion and the tubercles were closed and stabilized by these sutures. The two no2 vicryl sutures coming from the distal shaft were passed through the tubercles one by one and tied to fix the tubercles to the shaft of the humerus. Spongios bone allograft was used in case of comminution in the metaphysis and "strut" bone allograft was used in case of non-integrity in the medial metaphysis.

Postoperative Management

All the patients used a sling for the first 3 weeks postoperatively. Shoulder pendulum exercises, full active ROM exercises of the elbow and grip exercises of the hand were begun in this period. After 3 weeks postoperatively, patients stopped using the sling and active assistive forward flexion and abduction exercises of the shoulder

were started, but shoulder rotation was not allowed. After 6 weeks postoperatively all active ROM exercises including rotation were allowed. Weight lifting was inhibited till 12 weeks postoperatively. The patients were evaluated clinically and radiologically in 3-week, 6-week, 3-month, 6-month, 1-year and final follow-up sequentially.

Statistical Analysis

In this study statistical analyses have been carried out by NCSS (Number Cruncher Statistical System) and package programme of 2007 Statistical Software (Utah. USA). The data were statistically evaluated not only by means of definitive methods (average, standard deviation, median, interquartile range) but also comparative methods such as Mann-Whitney U test for comparing two groups, Kruskal Wallis test for the groups more than two, Dunn's multiple-test for sub-groups, Ki-square test for categorical data. P values less than 0.05 is identified as statistically significant.

Results

Fourteen(56%) patients were male, eleven(44%) were female; mean age was 58(28-92). There were 7(%28) two-part, 6(%24) three-part, 12(%48) four-part fractures according to Neer classification and 8 (%32) Type A, 2 (%8) Type B, 15 (%60) Type C fractures according to AO classification. Philos® locking plate was applied to all of the patients. The mean follow-up duration was 25(14-82) months. There were 7(%28) patients who had concomitant injuries. 1-ipsilateral humerus distal fracture, 2-Cruris type 3 open fracture 3-ipsilateral humerus fracture 4-ipsilateral olecranon fracture 5- ipsilateral olecranon fracture 6-contralateral floating elbow 7-hemotoraks+ head trauma. Bone allograft was used in 3 (%12) patients- femoral strut in 1 patient, spongios allograft in 2 patients.

Clinical Results

Shoulder ROM values were measured as mean 130 (IQR 107-165) degrees of flexion, 125 (IQR 100-145) degrees of abduction and 40 (IQR 20-60) degrees of external rotation. The internal rotation degree was detected according to the level of the hand reaching to the body and measured as the dorsum of the hand at gluteus maximus in 3 patients, L5 in 1 patient, L3 in 10 patients, T12 in 7 patients and between the scapulas in 4 patients.

The median Constant score was 80(IQR 60-89). There were 7(28%) excellent, 9(36%) good, 5(20%) fair, 4(16%) poor results according to Constant shoulder score (Fig. 1). The median ASES score was 80(IQR 60-95). There were 10 (40%) excellent, 5 (20%) good, 7(28%) fair, 3(12%) poor results according to ASES shoulder score (Fig. 2).

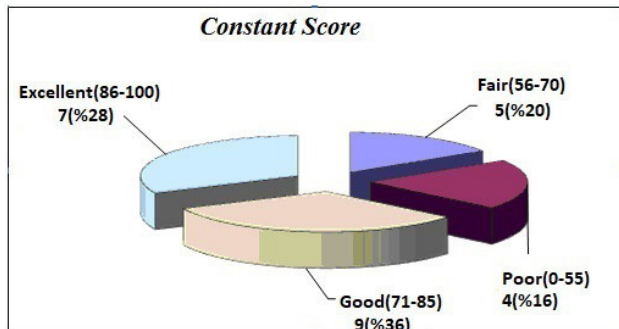


Figure 1

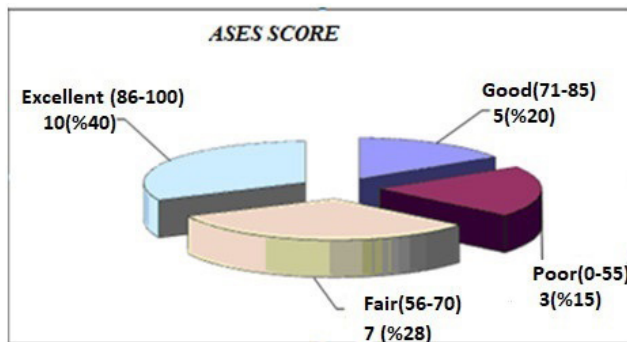


Figure 2

Age, gender, fracture type and concomitant injuries had no effect significantly neither on Constant nor on ASES scores (Tables I,II,III).

Table 1: Statistical analysis showing the effect of age and gender on Constant and ASES shoulder scores.

		N:18	N:7		
		<60 Age	≥60Age	MW	P
	Ort±SS	76,18±18,6	72,88±18,76		
Constant Score	Median	82 (60-91)	77 (58-85,25)	56,5	0,502
	Ort±SS	76,35±18,25	81,13±18,47		
ASES	Median	80 (60-93)	84 (61-99,5)	56,5	0,501
		N:14	N:11		
		Male	Female	MW	P
	Ort±SS	79,43±16,21	69,64±20,13		
Constant Score	Median	82,5 (63,75-92)	79 (55-83)	53	0,188
	Ort±SS	81,57±14,8	73,18±21,36		
ASES	Median	82,5 (67,5-95,75)	80 (55-95)	56,5	0,260

*MW: Mann-Whitney

Table 2: Statistical analysis showing the effect of Neer and AO fracture types on Constant and ASES shoulder scores.

		N:7	N:6	N:12		
		NEER 2	NEER 3	NEER 4	KW	P
Ort±SS		79,14±14,39	82,83±15,94	68,92±20,48		
Constant Score	Median	80 (75-87)	84 (65,25-100)	73 (55,25-88,75)	2,53	0,282
Ort±SS		85,86±13,98	79,17±16,56	72,58±20,25		
ASES	Median	88 (80-98)	77,5 (66,25-96,25)	75 (58,5-90,25)	2,33	0,312
		N:8	N:2	N:15		
AO Type		A	B	C	KW	P
Ort±SS		79,63±13,39	92,50±10,61	70,40±19,98		
Constant Score	Median	81,50 (76,25-86)	92,5 (63,75-95)	67 (56-91)	3,62	0,164
Ort±SS		84,50±13,50	87,50±10,61	73,07±19,95		
ASES	Median	84 (76,25-97,25)	87,5 (66-91,25)	70 (58-91)	2,28	0,320

Dunn's Multipl Comparing Test	Constant Score	ASES
A / B	0,115	0,895
A / C	0,301	0,174
B / C	0,117	0,370

*KW: Kruskal-Wallis

Table 3: Statistical analysis showing the effect of concomitant injuries on Constant and ASES shoulder scores.

		N:7	N:18		
		PHFs with concomitant injuries	Isolated PHFs	MW	P
Ort±SS		75,83±17,36	73,28±21,99		
Constant Score	Median	79,5 (61,5-89)	83 (51-91)	63	0,999
Ort±SS		79,72±16,77	73,14±21,76		
ASES	Median	82,5 (60-95,75)	80 (60-91)	52	0,504

*MW: Mann-Whitney

Radiological Results

Boileau neck-shaft inclination angle was found to be mean 135 (IQR 120-144) degrees. Three patients (12%) had varus malunion and three patients (12%) developed AVN which was evaluated as Stage 4 according to Cruess Classification.

Complications

Eleven patients (44%) had complications. 4 patients had more than one complication. Totally there were 15 complications which can be listed (Table IV). Revision surgery was proposed to 5 of the 11 patients complicated; 1 had AVN+high placed plate, 1 had varus malunion+high placed plate, 1 had AVN+screw cut-out, 1 had arthrosis due to neglected glenoid fracture and 1 had lysis of the greater tubercle. 3 patients refused further surgery and AVN+high placed plate case had hemiarthroplasty and arthrosis case had total shoulder arthroplasty. 2 patients with screw cut-out and 1 patient with metaphyseal angulation did not need any further surgical intervention as the complications noted did not worsen the clinical outcome. The brachial plexus palsy was transient, it healed completely. Of the remaining 3 patients, one had AVN and 2 had varus malunion with "moderate" results finally. The main complaint was restriction of motion in these patients and they were doing the daily activities without difficulty. No further intervention was planned eventually. The patients with complications had significant worse clinical results (lower Constant and ASES shoulder scores) than the patients without complications ($p=0,005$ and $p=0,005$ respectively) (Table V).

Table 4: Complications

	N	%
AVN	3	12
Varus Mal-union	3	12
Screw cut-out	3	12
High placed plate	2	8
Artrosis	1	4
Brachial plexus palsy	1	4
Metaphyseal angulation	1	4
Lysis of the greater tubercle	1	4
*AVN: avascular necrosis		

Table 5: Statistical analysis showing the effect of complications on Constant and ASES shoulder scores.

		N:14	N:11		
		Complication (-)	Complication (+)	MW	P
	Ort±SS	81,53±13,45	57,83±17,63		
Constant Score	Median	83 (75-91)	56,1 (38,5-70,75)	13	0,005
Ort±SS		83,84±14,27	63±16,52		
ASES	Median	88 (75-95)	63,1 (49-72,5)	13,5	0,005
*MW: Mann-Whitney					

Discussion

This study had three noteworthy findings. One was dealing with the tips of surgical technique which informed that one should never place the plate high. The other one concluded that the outcome after locking plate osteosynthesis of PHFs had favorable results. The last one was about the complications delineating that AVN and varus malunion led to worse results.

It has been reported that functional results of patients under 65 years of age were better than patients over 65 years of age and this difference was related to osteoporosis seen in elderly patients which lead to "screw-cut out" complication¹⁴. On the other hand, another study found no difference between the functional results of two groups of patients who were under and over 60 years of age.^[15] In the present study, there was no significant difference between the clinical results (Constant and ASES shoulder scores) of the patients who were <60 years of age and the patients who were =>60 years of age. This result can be attributed to stable fixation of the fractures by locking plates and beginning the rehabilitation programme earlier.

It has been reported in various studies that Constant shoulder scores were "good" in Neer type 2 and type 3 fractures and "fair" in type 4 fractures treated surgically by locking plates.^[16,17,18,19,20,21] Robert el al informed that as the number of fracture pieces increased, the functional outcome of the patients treated surgically by locking plates get worse.^[18] In the current study, there was no significant difference between the Constant or ASES shoulder scores of Neer type 2, 3 and 4 fractures or AO type A, B and C

fractures. This can be interpreted as the clinical results of PHFs were not dependent on the fracture type, but on the complications recorded and complications can be seen in all of these fracture types.

Avascular necrosis of the humeral head after surgical treatment of PHFs with locking plates was reported as 0-15% in various studies.^[14,15,16,17,18,19,20] It was related to the arterial insufficiency due to the comminution at the fracture site or fracture-dislocation of the humeral head, or to excessive manipulation to reduce the fracture and excessive stripping of the soft tissues.^[15] The AVN rate was found to be 12% in the present study. All of the 3 patients had collum anatomicum fractures which could be a factor preceding AVN. Another factor to be considered was the age of 2 patients which was greater than 70; the remaining patient was 58 years of age but she had a fracture-dislocation as a stunning feature. We concluded that the fracture type, namely collum anatomicum fracture and fracture-dislocation and old age could be predisposing factors for AVN. The surgical tip we advocate to lower the AVN rate is to use the rotator interval to reach the humeral head which allows minimal stripping of the soft-tissues and reduce the humeral head gently with a periosteal elevator.

Screw cut-out was reported to be the most frequent complication leading revision surgery with an occurrence rate of 21%; 14% was primary screw cut-out (placing a long screw preoperatively) and 7% was secondary screw cut out (collapse of the humeral head due to metaphyseal osteoporosis during follow-up).^[22] It was recorded as 12% in the present study and all of the 3 screw cut-outs were secondary. The reason why we did not have any primary screw cut-out can be attributed mainly to the surgical technical tip performed, which was drilling only the cortex and the first 2-cm of the screw pathway and then measuring the screw length by the gauge to the point where the gauge engaged the hard subchondral bone. The other technical tip was taking 3 successive scopy images, namely AP, AP in external rotation and AP in internal rotation to determine the screw length and position were appropriate.

In another study, varus malunion was reported the most frequent complication with a rate of 16%¹⁸. It was detected with a rate of 12% in this study. When the 3 patients with varus malunion analyzed, it was detected that one had a technical error in surgery; the plate was placed high. The other two had short inferomedial screws that did not support the humeral calcar. We concluded that

the proper placement of the plate 1cm below the tip of the greater tuberosity and the use of inferomedial calcar screw long enough are two important factors that avoid varus malunion.

Revision surgery rates for surgical treatment of PHFs with locking plates were informed as %9-25.^[23] The complications which required revision surgery were reported in frequency order as screw cut-out, varus mal-union, AVN, subacromial and implant failure.^[14,15,18] The revision surgery rate was 20% in the present series. Among the 5 patients who needed revision surgery, 2 AVN, 2 technical errors in surgery (1 high placement of the plate, 1 screw cut-out), 1 neglected glenoid fracture and 1 lysis of the greater tubercle were noted. We concluded that in order to avoid revisions after locking plate of PHFs, a keen surgical technique delineated by the surgical tips of this manuscript, precautions to avoid AVN and a detailed glenoid fracture examination preoperatively with CT should be carried out.

A considerable issue to be discussed for the management of PHFs is when to choose fixation or arthroplasty options primarily. Hemiarthroplasty which was first introduced by Neer can be a solution for Neer 3 or 4 part comminuted fracture or fracture dislocations. The key point for success is tuberosity healing and best results can be obtained in younger patients and patients with less tuberosity comminution. Besides, reverse shoulder arthroplasty proposed by Grammont has become a pioneer treatment for the comminuted PHFs in the elderly people who have dysfunctional rotator cuffs additionally. On the other hand, prosthetic options have plenty serious complications; mainly aseptic loosening, instability, infection, reflex sympathetic dystrophy and periprosthetic fractures.^[24,25] Looking at the fixation site, it has sufficient results if anatomic reduction and stable fixation can be obtained. However, it is fraught with complications^[26,27], the rate of which was reported as 44% in this study. On the other hand, the revision rate was 20% which denoted that all of the complications did not require any further intervention as they did not bother daily activities of the patients and so were well tolerated. It was concluded that favorable results were obtained by locking plates in the management of PHFs in all fracture types and age groups if the surgical tips delineated in this study were accomplished and AVN complication did not proceed. AVN was the major complication leading poor results and revisions.

The pros of the study are the outcomes given after a minimum follow-up of 14 months and mean follow-up of 2 years. Limitations of this study include its retrospective design and the small number of patients being involved. The number of patients in the subgroups of the collected data on certain variables- age, gender, fracture type, concomitant injury- could make reaching statistically significant differences difficult which would lead to type II error. The other limitation is that the confounding factors such as smoking, diabetes, chronic kidney disease were not questioned. Lastly, the whole number of patients who were treated operatively or non-operatively for PHF in the study period and the patients who had surgery but were lost to follow-up were not recorded.

Conclusions

The treatment of PHFs by locking plates had favorable results in all fracture types and age groups if complications were being avoided. Major complications leading to poor results were AVN, varus malunion and technical errors in surgery. AVN was the leading cause for revisions and poor results.

Declarations

Conflict of interest

The authors declare that they have no conflict of interest.

Funding Statement

The author does not declare any funding.

Ethics Approval

Ethical approval (Date/Number: 2023/) was obtained from the ethical committee of a university.

Ethical Approval

The study was approved by the Haydarpasa Numune Education and Research Hospital Ethical Committee (date 09.02.2023 and number E-62977267-771-209014806)

Availability of Data And Material

Available.

Authors' Contributions

All authors have made substantial contributions to this article being submitted for publications. All authors critically reviewed the manuscript and approved the final form.

References

1. Laux CJ, Grubhofer F, Werner CML, Simmen HP, Osterhoff G. Current concepts in locking plate fixation of proximal humerus fractures. *J Orthop Surg Res.* 2017;12:137.
2. Panagiotopoulou VC, Varga P, Richards RG, Gueorguiev B, Giannoudis PV. Late screw-related complications in locking plating of proximal humerus fractures: A systematic review. *Injury* 2019;50:2176-2195.
3. Chen H, Zhu ZG, Li JT, Chang ZH, Tang PF. Finite element analysis of an intramedullary anatomical strut for proximal humeral fractures with disrupted medial column stability: A cohort study. *Int J Surg.* 2020;73:50-56.
4. Osterhoff G, Ossendorf C, Wanner GA, Simmen HP, Werner CM. The calcar screw in angular stable plate fixation of proximal humeral fractures--a case study. *J Orthop Surg Res.* 2011;24:6:50.
5. Katthagen JC, Lutz O, Voigt C, Lill H, Ellwein A. Cement augmentation of humeral head screws reduces early implant-related complications after locked plating of proximal humeral fractures. *Obere Extrem.* 2018;13:123-9.
6. Warnhoff M, Jensen G, Dey Hazra RO, Theruvath P, Lill H, Ellwein A. Double plating-surgical technique and good clinical results in complex and highly unstable proximal humeral fractures. *Injury* 2021;52:2285-91.
7. Schnetzke M, Bockmeyer J, Loew M, Studier-Fischer S, Grützner PA, Guehring T. Rate of avascular necrosis after fracture dislocations of the proximal humerus: Timing of surgery. *Obere Extrem.* 2018;13(4):273-8.
8. Neer CS. Articular replacement for the humeral head. *J Bone Joint Surg Am.* 1955;37-A(2):215-228.
9. Jakob RP, Ganz R. Proximale Humerusfrakturen. *Helv Chir Acta.* 1981;48(5):595-610.
10. Boileau P, Walch G. The tree-dimensional geometry of the proximal humerus. *J Bone Joint Surg Br.* 1997;79(5):857-865.
11. Brooks CH, Revell WJ, Heatley FW. Vascularity of the humeral head after proximal humeral fractures: an anatomical cadaver study. *J Bone Joint Surg Br.* 1993;75(1):132-136.
12. Constant CR, Murley AH. A clinical method of functional assessment of the shoulder. *Clin Orthop Relat Res.* 1987;214:160-164.
13. Michener LA, McClure PW, Senneth BJ. American Shoulder and Elbow Surgeons Standardized Shoulder Assessment Form, patient self-report section: reliability, validity, and responsiveness. *J Shoulder Elbow Surg.* 2002;11(6):587-594.
14. Clavert P, Adam P, Bevort A, Bonnomet F, Kempf JF. Pitfalls and complications with locking plate for proximal humerus fracture. *J Shoulder Elbow Surg.* 2010;19(4):489-494.
15. Egol KA, Ong CC, Walsh M, Jazrawi LM, Tejwani NC, Zuckerman JD. Early complications in proximal humerus fractures (OTA Types 11) treated with locked plates. *J Orthop Trauma* 2008;22(3):159-164.
16. Owsley KC, Gorczyca JT. Fracture displacement and screw cutout after open reduction and locked plate fixation of proximal humeral fractures [corrected]. *J Bone Joint Surg Am.* 2008;90(2):233-240.
17. Helwig P, Bahrs C, Epple B, Oehm J, Eingartner C, Weise K. Does fixed-angle plate osteosynthesis solve the problem of a fractured proximal humerus? A prospective series of 87 patients. *Acta Orthop.* 2009;80(1):92-96.

18. Sproul RC, Iyengar JI, Zlatko Devcic Z, Feeley BT. A systematic review of locking plate fixation of proximal humerus fractures. *Injury* 2011;42(4):408-413.
19. Rouleau DM, Laflamme GY, Berry GK, Harvey EJ, Delisle J, Girard J. Proximal humerus fractures treated by percutaneous locking plate internal fixation. *Orthop Traumatol Surg Res.* 2009;95(1):56-62.
20. Agudelo J, Schürmann M, Stahel P, Helwig P, Morgan SJ, Zechel W, Bahrs C, Parekh A, Ziran B, Williams A, Smith W. Analysis of efficacy and failure in proximal humerus fractures treated with locking plates. *J Orthop Trauma* 2007;21(10):676-681.
21. Iacobellis C, Fountzoulas K, Aldegheri R. Plating of proximal fracture of the humerus: a study of 30 cases. *Musculoskelet Surg.* 2011;95 Suppl-1:S43-48.
22. Solberg BD, Moon CN, Franco DP, Paiement GD. Surgical treatment of three and four-part proximal humeral fractures. *J Bone Joint Surg Am.* 2009;91(7):1689-1697.
23. Handschin AE, Cardell M, Contaldo C, Trenzt O, Wanner GA. Functional results of angular-stable plate fixation in displaced proximal humeral fractures. *Injury* 2008; 39(3):306-313.
24. Grassi FA, Alberio R, Ratti C, Surace MR, Piazza P, Messinese P, Saccomanno MF, Maccauro G, Murena L. Shoulder arthroplasty for proximal humerus fractures in the elderly: The path from Neer to Grammont. *Orthop Rev. (Pavia)* 2020;12(Suppl 1):8659.
25. Gigis I, Nenopoulos A, Giannikas D, Heikenfeld R, Beslikas T, Hatzokos I. Reverse shoulder arthroplasty for the treatment of 3 and 4-part fractures of the humeral head in the elderly. *Open Orthop J.* 2017; 11:108-118.
26. Schliemann B, Siemoneit J, Theisen C, Kösters C, Weimann A, Raschke MJ. Complex fractures of the proximal humerus in the elderly—outcome and complications after locking plate fixation. *Musculoskelet Surg.* 2012; 96 Suppl 1:S3-11.
27. Jordan RW, Modi CS. A review of management options for proximal humeral fractures. *Open Orthop J.* 2014; 8:148-56.